

## Original Article

# Prevalence of Oral Manifestations of Iron Deficiency Anemia in a Sample of Egyptian Population. A Hospital-Based Cross-Sectional Study

EmanAlsheikh<sup>1</sup>, Eman Amr<sup>1</sup>, Fatheya Zahran<sup>1</sup>

<sup>1</sup> Department of Oral Medicine and Periodontology, Faculty of Dentistry, Cairo University

E-mail: eamr08@gmail.com

Received: 04-07-2019

Accepted For Publishing: 13-10-2019

## Abstract

**Background:** Iron deficiency anemia (IDA) patients have specific oral manifestations and a particular blood profile as compared to normal individuals as well as significantly higher frequencies of all oral manifestations.

**Methods:** The study was conducted on 180 patients attending the Hematology Department in Kasr Al Ainy Hospital and diagnosed as having IDA, the history was taken from patients through an interview with the investigator and followed by clinical examination to determine if they had any generalized symptoms and signs of anemia. The oral complaints and the presence of oral mucosal changes were recorded. The diagnosis of any of the forms of oral mucosal lesions was done mainly on clinical basis, depending on the recognition of the lesion.

**Results:** The results showed that the prevalence of oral manifestations at different Hb levels in the IDA patients included high frequency of oral lesions such as: pallor (97.2%), atrophic glossitis (AG) (34.4%), fissured tongue (24.4%), and low frequency of: recurrent aphthous ulcer (RAU) (6.1%), burning sensation of the oral mucosa (2.2%), angular cheilitis (AC) (1.1%), oral pigmentation (1.1%), geographic tongue (GT) (1.1%), and oral lichen planus (OLP) (0.6%).

**Conclusion:** Patients with IDA had special oral manifestations. In the light of the particular blood and iron profile detected in our patients, neither Hb level nor serum iron or ferritin level were showing any significant association with the presence of oral manifestations. Within the limitations of the current study, the only significant association was found between RAU and the duration of anemia.

**Keywords:** Atrophic glossitis, burning sensation, IDA, oral manifestations, fissured tongue.

## 1. Introduction

Iron deficiency anemia (IDA) is a decrease in the total Hb levels caused by a lack of sufficient iron (Goldenring, 2003). Globally, IDA affects more than 3.5 billion people. ID seems to be the only micronutrient deficiency that high income and low

income countries have in common (Watts, 2004). The prevalence of IDA was 30.2% in a study conducted among 932 girls in Egypt. Among the anemic girls, the prevalence of mild anemia was 89.6%, moderate anemia was 9.9% and 0.5% had severe anemia (Mousa et al., 2016).

The underlying causes of IDA can be either physiological or pathological. Physiological ID occurs at the times of increase iron requirements in response to periods of growth and development including infancy, adolescence and pregnancy. Pathological ID generally results from blood loss or malabsorption (Clarke and Dodds, 2014). The most frequent etiology in women of childbearing age is excessive menstrual loss, while in postmenopausal women and in males digestive diseases are the main causes (Bermejo and García-López, 2009). IDA is an important disease in older adults because of the potential underlying disorders such as gastrointestinal ulcers, tumors, arteriovenous malformations and malabsorption disorders. Furthermore, the underlying cause for the IDA is often multifactorial in older patients (Joosten, 2018).

Common signs and symptoms of IDA result from hypoxic functioning are: difficulties with memory and concentration (cognitive), fatigue, sluggishness, tiring easily, low energy level, feeling mildly light-headed, and pale conjunctiva, mucosa or skin. Exertional dyspnea progressing to breathlessness at rest, vertigo, syncope (Quinn et al., 2004), headache (Bergsjø et al., 2008) and tachycardia (Matteson et al., 2012, Besarab and Hemmerich, 2018) were also described.

The diagnosis of anemia is through physical examination, signs, symptoms and hematologic laboratory findings. Serum ferritin levels can be evaluated along with the hemoglobin (Hb) level in routine blood counts (Derossi and Raghavendra, 2003). History (hematemesis, melena, hematuria, uterine blood loss, weight loss and previous gastrointestinal surgery), drug use (non-steroidal anti-inflammatory drugs, aspirin, anticoagulants, corticosteroids, proton pump inhibitors) and clinical examination remain the cornerstone of the initial approach to the older patient with IDA (Auerbach and Adamson, 2016). Patients were diagnosed as having IDA when men had Hb < 13 g/dL, women had Hb < 12 g/dL, and all of them had serum iron level < 60 mg/dL according to the World Health Organization criteria (WHO, 2001).

Oral symptoms and signs of IDA may include mucosal pallor, atrophic glossitis (AG), generalized oral mucosal atrophy, anemic stomatitis, angular cheilitis (AC), tenderness or burning sensation of oral mucosa, various types of oral candidiasis, lingual varicosities, recurrent aphthous ulcers (RAU), dry mouth, and dysfunction of taste (Wu et al., 2014). Other miscellaneous oral manifestations found in patients of IDA in various studies include hyperpigmentation and oral lichen planus (OLP) (Lu, 2016). Thus IDA patients

have specific oral manifestations and a particular blood profile as compared to normal individuals as well as significantly higher frequencies of all oral manifestations (Wu et al., 2014).

To further understand the relation between IDA and oral mucosal lesions, this cross-sectional study was designed to determine the prevalence of oral manifestations at different Hb levels, among a sample of Egyptian patients with IDA attending the Hematology Department in Kasr Al Ainy hospital.

## 2. Subjects and Methods

The present investigation was conducted on 180 patients attending the Hematology Department in Kasr Al Ainy Hospital Cairo University, and diagnosed as having IDA. These patients represented all those attending the department, and fulfilling our inclusion criteria, within a 6 months period, from the 1st of May till the 9th of November, 2018. They were diagnosed with IDA, according to their Hb, ferritin and serum iron records. In the present study patients suffering from any other systemic diseases known to influence oral and maxillofacial manifestations, patients suffering from any other systemic diseases known to cause IDA as secondary condition, patients on drug therapy that may have oral mucosal manifestations, lesions due to existing local factors for example traumatic ulcer on the tongue because of sharp tooth against tongue, AC because of poor denture design, and also patients with malignancy, were excluded. For each eligible participant, a full history was obtained according to an assessment sheet; patients were asked about their medical history, diet, previous and recent medication, previous operations, abnormal bleeding history, and previous care regarding sore mouth.

The history taken from patients was followed by clinical examination which was done through an interview between the investigator and the patient. Patients were clinically examined to determine if they had any generalized symptoms and signs of anemia such as weakness, tiredness, exertional dyspnea, pallor, tachycardia, and postural hypotension; (examination of generalized symptoms and signs was done by the hematologist in the presence of the principal investigator).

The oral complaints and the presence of oral mucosal changes were recorded. The diagnosis of any of the forms of oral mucosal lesions was done mainly on clinical basis, depending on the recognition of the lesion. Mobile light source was used with dental mirror and gloves, the oral examination started with elevation of the

lips for cracking, fissuring or color changes. Mucosal alterations were assessed, the tongue was manipulated by the examiner by grasping the tip with cotton gauze, and the vestibules were examined by retracting buccal mucosa.

To further understand the relation between IDA and oral mucosal lesions, this cross-sectional study was designed to determine the prevalence of oral manifestations at different Hb levels, among a sample of Egyptian patients with IDA attending the Hematology Department in Kasr Al Ainy hospital.

### Sample size calculation:

Under the assumption that almost 50% of patients with IDA have oral mucosal lesions, the calculated sample size for the present study was 163 patients within an acceptable margin of error of about 5%, 95% confidence interval (CI), and a power of 80%. The present study utilized a non-probability, consecutive, sampling technique to recruit eligible patients. Sample size calculation was conducted using STATCALC of Epi Info™ (version 7.2.1.0)

### Statistical analysis

All variables recorded during the study were summarized. Statistical analyses were performed using the statistical software program, SPSS, for Windows version 20.0 (SPSS; Chicago, IL, USA).

Our variables were normally distributed according to the Kolmogorov-Smirnov test. Therefore, frequencies and percentages were provided for categorical variables; while, Mean and standard deviation (SD), were provided for continuous variables. Chi square test and its subsidiaries were used to detect the significant change in categorical variables; while, t-test was used for continuous variables. A p-value of less than 5% was considered statistically significant.

### 3. Results

The 180 subjects included in the study were 174 females (96.7%) and 6 males (3.3%). The mean ±SD values for age were 32.6 ±10.4 years old with a minimum of 15 and a maximum of 62 years old.

The mean Hb level (g/dL), Serum iron (µg/dL), and Ferritin (ng/mL) are shown in table 1.

The oral findings in the studied sample included high frequency of oral lesions such as: pallor was observed in

175 cases representing 97.2% of studied sample, AG was observed in 62 cases representing 34.4% of the study sample, fissured tongue was observed in 44 cases representing 24.4% of the study sample, in addition to low frequency of: RAU was observed in 11 cases representing 6.1% of the study sample, burning sensation of the oral mucosa was observed in 4 cases representing 2.2% of the study sample, AC was observed in 2 cases representing 1.1% of the study sample, oral pigmentation was observed in 2 cases representing 1.1% of the study sample, GT was observed in 2 cases, one male and one female, representing 1.1% of the study sample, and OLP was observed in 1 case representing 0.6% of the study sample, figure 1.

Comparing the presence of oral mucosal lesions with the level of IDA, it revealed no statistically significant association between the level of IDA and any of the oral mucosal lesions (P>0.05), table 2.

Regarding the presence of oral mucosal lesions with the different levels of IDA among all studied sample, and as shown by the table, pallor and AG, which are the most common oral manifestations, show the highest prevalence with moderate IDA. However, RAU shows the highest prevalence with severe IDA, while fissured tongue shows the lowest prevalence with life-threatening IDA, table 2.

The mean ± SD values for the duration of anemia were 10.5 ± 16.3 months with a minimum of 1 month and a maximum of 156 months. Regarding the correlation between the duration of anemia and the oral mucosal lesions, RAU was the only oral mucosal lesion showing a significant correlation with the duration of anemia (P=0.04), table 3. The results indicate the increase in the duration of IDA, there is a significant increase in the prevalence of RAU.

**Table 1:** Descriptive statistics for laboratory investigations

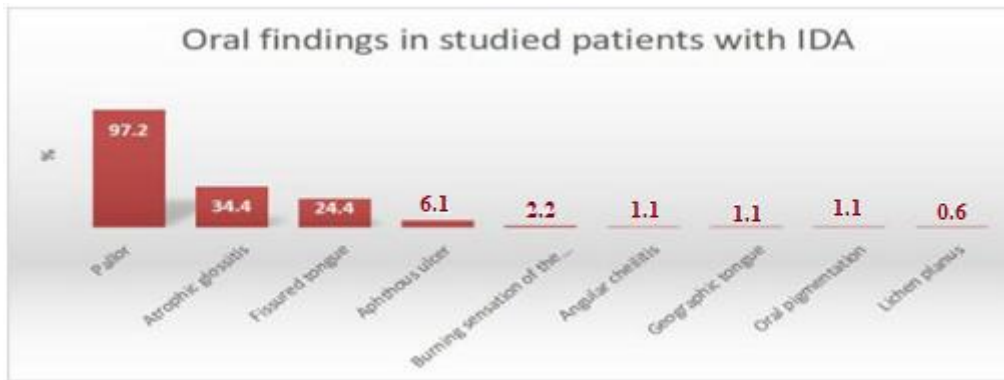
Laboratory Investigations	Mean (SD)	95% CI
Hb Level (g/dL)	8.77 (1.49)	8.55-8.99
Serum Iron (µg/dL)	24.19 (10.79)	22.6-25.78
Ferritin (ng/mL)	9.73 (14.16)	7.65-11.81

**Table 2:** Frequency of oral mucosal lesions according to the levels of IDA

oral mucosal lesions		Mild IDA		Moderate IDA		Severe IDA		Life-threatening IDA		P value of Chi <sup>2</sup> test
		Count	%	Count	%	Count	%	Count	%	
<b>Pallor=175</b>	Yes	53	30.3%	63	36.0%	48	27.4%	11	6.3%	0.779
	No	2	40.0%	1	20.0%	2	40.0%	0	0.0%	
<b>AG=62</b>	Yes	14	22.6%	29	46.8%	14	22.6%	5	8.1%	0.078
	No	41	34.7%	35	29.7%	36	30.5%	6	5.1%	
<b>AC=2</b>	Yes	0	0.0%	0	0.0%	2	100.0%	0	0.0%	0.154
	No	55	30.9%	64	36.0%	48	27.0%	11	6.2%	
<b>RAU=11</b>	Yes	2	18.2%	3	27.3%	5	45.5%	1	9.1%	0.512
	No	53	31.4%	61	36.1%	45	26.6%	10	5.9%	
<b>Fissured Tongue=44</b>	Yes	11	25.0%	14	31.8%	14	31.8%	5	11.4%	0.285
	No	44	32.4%	50	36.8%	36	26.5%	6	4.4%	
<b>Burning sensation of oral mucosa=4</b>	Yes	0	0.0%	3	75.0%	1	25.0%	0	0.0%	0.347
	No	55	31.3%	61	34.7%	49	27.8%	11	6.3%	
<b>Geographic Tongue=2</b>	Yes	0	0.0%	1	50.0%	0	0.0%	1	50.0%	0.06
	No	55	30.9%	63	35.4%	50	28.1%	10	5.6%	
<b>Oral Pigmentation=2</b>	Yes	0	0.0%	1	50.0%	1	50.0%	0	0.0%	0.748
	No	55	30.9%	63	35.4%	49	27.5%	11	6.2%	
<b>OLP=1</b>	Yes	0	0.0%	0	0.0%	1	100.0%	0	0.0%	0.455
	No	55	30.7%	64	35.8%	49	27.4%	11	6.1%	

**Table 3:** Correlation between the duration of anemia and the oral mucosal lesions

		Duration of anemia (months)		P value
		Mean	±SD	
Pallor	Yes	11.3	±20.6	0.09
	No	21.5	±25.8	
AG	Yes	10.1	±14.4	0.32
	No	12.9	±24.5	
AC	Yes	38.0	±48.1	0.43
	No	11.1	±20.0	
RAU	Yes	35.0	±59.7	<b>0.04</b>
	No	10.1	±14.8	
Fissured Tongue	Yes	11.0	±13.8	0.98
	No	11.9	±22.5	
Burning Sensation of oral mucosa	Yes	4.0	.	-
	No	11.8	±20.9	
Geographic Tongue	Yes	36.0	.	-
	No	11.4	±20.7	
Oral Pigmentation	Yes	96.0	.	-
	No	10.8	±19.0	
OLP	Yes	.	.	-



**Figure 1:** Bar chart representing distribution of oral findings in studied patients with IDA in the study sample

#### 4. Discussion

In the present study, convenience sampling was used, which is a type of non-probability or non-random sampling where members of the target population that meet certain practical criteria (Dörnyei and Griffie, 2010).

Up to the author's knowledge, this is the first study to check the prevalence of oral manifestations of IDA Egyptian patients.

The present study was conducted on 180 patients: 6 males (3.3%) and 174 females (96.7%), and this indicated that IDA is more prevalent in Egyptian females than in males,

the mean values for age were  $32.6 \pm 10.4$  years old with a minimum of 15 and a maximum of 62 years old.

The mean Hb concentration in the present study was  $9.6 \pm 10.2$  g/dl for males and  $8.77 \pm 10.5$  g/dl for females, revealing no significant difference between both genders. This mean Hb concentration was lower than that reported in the study by Wu et al. (2014) in which mean Hb level in males was 10.6 g/dl and mean Hb level in females was 10.5 g/dl. This difference between Hb means might be due to different sample size in both studies as in the present study patients were 180 (174 females and 6 males), but in that by Wu et al. (2014), the study sample size was only 75 patients (11 males and 64 females).

In the present study, 11 patients (6.1%) had life-threatening anemia, and 50 patients (27.8%) were severely anemic, 64 patients (35.6%) were moderately anemic, while mild anemia was observed in 55 of the included patients (30.6%); this clearly indicates that anemia in all the examined cases was not as severe as in the study by Lu (2016) who reported that 16% of patients had life-threatening IDA, 40% of patients were severely anemic, and 24% of cases were moderately anemic, last group were the mild anemic and they constituted 20% of patients. This variation of severity might be related to different sample size of both studies where 180 cases were examined in the present study, while Lu (2016) presented only 50 patients with IDA, also the various causes of IDA in both studies may have led to this difference.

In the current study, there was no significant association between Hb level and the detection of the oral lesions. This disagreed with Nayak et al. (2011) who stated that anemic patients develop oral manifestations after Hb level is reduced below 7 g/dl. The reason for these results can be due to lack of awareness of nutritional values, life style, decreased use of raw food and vegetables, and carelessness towards eating habits.

The most frequent oral manifestation yielded in the current study was pallor of oral mucosal tissues which was found in 175 cases represented 97.2% of the studied sample. Nayak et al. (2011) indicated that in their 78 cases diagnosed to have IDA, pallor of oral mucosa was seen in 20.51% of patients who had Hb level ranging from 5 – 7 g/dl in females and 4 – 9 g/dl in males. By comparing those findings to the current study; the Hb level for all studied cases was 8.5 – 8.9 g/dl. This indicated more severe anemia, with less prevalence of oral manifestations in the study conducted by Nayak et al. (2011).

In the current study, there was no significant association between both, the ferritin level ( $P=0.172$ ) and Hb level ( $P=0.779$ ) and pallor of the oral mucosa. This disagreed with Shrotriya and Shrotriya. (2018) who reported a strong association of oral manifestations, with the hematological

values, their results fortified the concept that oral signs can be used to evaluate the Hb and ferritin levels in the set-ups with limited laboratory facilities, also their results confirmed that oral manifestations were highly sensitive and specific to predict the hematological and serum ferritin modality of patients. They concluded that certain signs like cheilitis and complete glossitis were late indicators of IDA. This disagreement might be due to more severe anemia detected in Indian patients in the study by Shrotriya and Shrotriya. (2018) than in the present study (their severe anemic patients were 77 males and 113 females both with mean Hb level less than 8 g/dl).

The prevalence of AG detected in the present study (34.4%) was less than that reported by a retrospective British study conducted by Beveridge et al. (1965) where the AG was detected in 39% of their study sample, also lower than 35.1% detected in another British study conducted by Jacobs and Cavill, (1968). In the present study all patients with partial or complete, mild or severe glossitis were reported all as AG, so the total mentioned is the maximum count that could be deduced from the present study. However, the results of the current work, regarding AG, showed higher in prevalence comparison to the study carried out by Wu et al. (2014) where the AG was 26.7% of their study samples as well as a study by Sadri et al. (2012), where AG was found in 25% of the cases. The variation between results of the previous studies and the present one might be due to difference in the inclusion and exclusion criteria.

In the third place after pallor and AG respectively, fissured tongue occupied 24.4% of the detected lesions, 50 % of males and 23.6% of females. The current study results revealed no significant association between the level of IDA and fissured tongue ( $P= 0.285$ ). This might indicate that fissured tongue is not associated with specific age as it is referred to the presence of IDA; as it was presented in different age groups in all studied cases.

RAU constituted 6.1% among all detected oral lesions in the whole study sample, 5% of them were females and 1.1% were males. Results revealed no significant association between the level of IDA and RAU ( $P= 0.512$ ).

The current study percentage is approximately equivalent to that in the Taiwanese study by Lu (2016) where recurrent oral ulcers constituted 6% of their study sample. However, the 6.1% prevalence of RAU in the current study was lower than that reported by Wu et al. (2014) where RAU were detected in 25.3% of the studied cases from a Taiwanese population. This variation might be due to different factors implicated in the etiology of RAU in the studied populations.

In the current study, burning sensation of the oral mucosa constituted 2.2% of the detected oral mucosal lesions

among the whole study sample. This percentage is extremely lower than that reported by Wu et al. (2014); where patients complaining of burning sensation of oral mucosa were representing 76.0% of the whole study sample. Also the current study disagreed with Shrotriya and Shrotriya. (2018) who reported that 66.5% of cases complained of burning sensation. This variation might be due to difference in exclusion criteria adopted in the studies.

Although AC is a common manifestation of anemia in most studies (Lu, 2016), and had been mentioned as a representative lesion of IDA in an indian case report presented by Nilofer et al. (2018) this was not evident in our study where AC constituted only 1.1% of oral mucosal lesions, and this percentage is exceedingly lower than that reported in an iraqian study conducted by Zaidan (2008) who reported 35.3% prevalence of AC. Our results also disagreed with Beveridge et al. (1965), and Lu (2016), where AC represented 14%, and 63% respectively.

The lack of high prevalence of AC in the present study could be due mainly to the exclusion of patients with systemic conditions that lead to secondary IDA. Such systemic conditions might be the real cause behind candidal infection that leads to AC appearance.

An indian study conducted by Joshi et al. (2016) revealed that gingival pigmentation could be correlated with Hb concentration, a remark not mentioned in previous studies. That study reported a correlation between gingival pigmentation score in 44 children (53%), and their Hb concentration which was found below 11 g/dl, ( $P < 0.05$ ).

However, the current study showed that the prevalence of oral pigmentation in IDA patients, irrespective to their Hb level, was only 1.1% of the whole study sample. The oral pigmentation had been detected in different sites such as buccal mucosa and dorsum of the tongue. One manifesting patient had severe anemia while the other had moderate anemia. In this present study oral pigmented lesions were never known if they were physiological or correlated to IDA. This concept will remain questionable because of lack of patient's knowledge if those pigments were already present or newly formed, also neither patient nor doctor can prove if the lesion occurrence was before or after IDA occurrence.

Geographic tongue (GT) was seen in 2 cases in this present study, one male and the other female, thus GT represented 1.1% of detected lesions within the whole study samples. However, no previous study had stated that GT was a clinical sign of IDA. The appearance of 2 cases in the present study could be an indication of a relation between the 2 conditions (IDA and GT) or might be a mere coincidence.

In the current study, OLP constituted 0.6% of the whole detected lesions. Only 1 female patient was found. However, this result disagreed with that mentioned in a study conducted by Chen et al. (2015) who reported that OLP was detected in 21.9%, and 13.6% of patients suffering from deficiencies of Hb, and iron, respectively. Also, our results were in disagreement with those reported by Wu et al. (2014) where 33.3% of IDA patients were diagnosed with OLP, concluding that OLP was one of the five leading oral manifestations for IDA. This variation in results might be related to the different population, selected study area, and difference in the selection criteria.

The correlation between the duration of anemia and the oral mucosal lesions detected in the current study revealed that RAU was the only oral mucosal lesion showing a significant correlation with the duration of anemia ( $P = 0.04$ ). With an increase in the duration of IDA, there was a significant increase in the prevalence of RAU. This could be explained by the cumulative effect of iron deficiency on oral mucosa on the long run. It could start as atrophic changes, then ulceration of the atrophic areas follow.

Thus as a whole, our results showed that patients with IDA had special oral manifestations with pallor, AG, fissured tongue and RAU showing higher frequency than the other lesions detected as: AC, burning sensation of oral mucosal tissues, GT, oral pigmentation and OLP which were found with less frequency. In the light of the particular blood and iron profile detected in our patients, neither Hb level nor serum iron or ferritin level were showing any significant association with the presence of oral manifestations.

## Conclusions

The oral manifestations of IDA among a sample of Egyptian patients attending the Hematology Department in Kasr Al Ainy Hospital included high frequency of oral lesions such as: pallor (97.2%), AG (34.4%), fissured tongue (24.4%), in addition to low frequency of: RAU (6.1%), burning sensation of the oral mucosa (2.2%), AC (1.1%), oral pigmentation (1.1%), GT (1.1%), and OLP (0.6%).

There is no significant association between the Hb level and the prevalence of any of the oral mucosal lesions.

There is a significant association between RAU and the duration of anemia, the more the duration, the higher the prevalence of RAU.

## Recommendations

Further studies are required with a larger sample size and more geographic extension to assess oral mucosal lesions in IDA patients.

More studies are needed to assess oral lesions in IDA patients in younger age groups in Egypt.

## References

1. Auerbach M, and Adamson JW. How we diagnose and treat iron deficiency anaemia. *American Journal of Hematology*, 91:31–38, 2016.
2. Bergsjø P, Evjen-Olsen B, Hinderaker SG, Oleking'ori N, Klepp KI. Validity of non-invasive assessment of anemia in pregnancy. *Tropical Medicine & International Health*.13:272–77, 2008.
3. Bermejo F, and García-López S. A guide to diagnosis of iron deficiency and iron deficiency anemia in digestive diseases. *World Journal of Gastroenterology*, 15:4638e43, 2009.
4. Besarab A, and Hemmerich S. Management of Anemia. *A Comprehensive Guide for Clinicians 10–29*. Springer science, 10.1007/978-1-4939-7360-6\_2, 2018.
5. Beveridge DR, Bannerman RM, Evanson JM and Witts LJ. Hypochromic Anaemia; a Retrospective Study and Follow-up of 378 Patients. *Quarterly Journal of Medicine*, 34, 145, 1965.
6. Chen HM, Wang YP, Chang JY, Wu YC, Cheng SJ, Sun A. Significant association of deficiencies of hemoglobin, iron, folic acid, and vitamin B12 and high homocysteine level with oral lichen planus. *J Formos Med Assoc*. Feb;114(2):124-9, 2015.
7. Clarke L, and Dodds AJ. Iron deficiency anaemia, *Current Opinion in Gastroenterology*. 15(11), 2014.
8. Derossi SS, and Raghavendra S. Anemia. *Oral Surgery, Oral Medicine, Oral Pathology, Oral Radiology Endodontics*. 95(2):131-41, 2003.
9. Dörnyei Z and Griffee DT. *Research Methods in Applied Linguistics*. TESOL Journal, 1: 181-183, 2010.
10. Goldenring J. Iron deficiency anemia- children. *Medline plus Journal*, 56(6): 152-156, 2003.
11. Jacobs A and Cavill I. The oral lesions of iron deficiency anaemia: pyridoxine and riboflavin status. *British Journal of Haematology*, 14:(3), 291–295, 1968.
12. Joosten E. Iron deficiency anemia in older adults: A review. *Geriatrics & Gerontology International*, 18(3), 373–379, 2018.
13. Joshi DM, Arora V, and Dogra S □ Interrelationship between gingival pigmentation and hemoglobin concentration in children- A cross sectional study, 15(4), 74–76, 2016.
14. Lu SY. Perception of iron deficiency from oral mucosa alterations that show a high prevalence of Candida infection. *J Formos Med Assoc*. Aug;115(8):619-27, 2016.
15. Matteson KA, Raker CA, Pinto SB, Scott DM, Frishman GN. Women presenting to an emergency facility with abnormal uterine bleeding: patient characteristics and prevalence of anemia. *Journal of Reproductive Medicine*.57: 17–25, 2012.
16. Mousa S, Saleh S, Higazi A, Ali H. Iron deficiency and iron deficiency anemia in adolescent girls in rural upper Egypt. *International Blood Research & Reviews*, 5(4), 1–6, 2016.
17. Nayak P, Nayak S, Donoghue M. Prevalence and Oral Manifestations of Iron Deficiency Anemia: A Short Study, Sushruth, & Donoghue, ; Mandana. *Medico-Legal Update*, 2011.
18. Nilofer H, Chaithra Kalkur, Padmashree S, Anusha L R. Diagnosis of Iron Deficiency Anemia through Oral Manifestation - A Case Report. *JOJ Case Stud*, 7(4), 5–7, 2018.
19. Quinn JV, Stiell IG, McDermott DA, Sellers KL, Kohn MA, Wells GA. Derivation of the San Francisco Syncope Rule to predict patients with short-term serious outcomes. *Annals of Emergency Medicine*.43:224–32, 2004.
20. Sadri D, Moosavi A, Mohaghegh E. Relationship between Anemia and Sore mouth, *Journal of Dentomaxillofacial Radiology, Pathology and Surgery*.p, 15-18, 2012.
21. Shrotriya A, Shrotriya A. Oral Manifestations in Iron Deficiency Anemia. *Journal of Advanced Medical and Dental Sciences Research*. 2321-9599, 2018.
22. Watts RG. Neutropenia. In: *Wintrobe's Clinical Hematology*, 11th edn. Lippincott Williams & Wilkins, Philadelphia ; 1777–1800, 2004.
23. WHO/UNICEF/UNU. Iron deficiency anemia assessment, prevention, and control: a guide for program managers. Geneva, Switzerland: World Health Organization, 2001.
24. Wu YC, Wang YP, Chang JY, Cheng SJ, Chen HM, Sun A. Oral manifestations and blood profile in patients with iron deficiency anemia. *Journal of the Formosan Medical Association (JFMA)*.113: 83–87. Nutritional anaemias, 2014.
25. Zaidan TF. Angular cheilitis and iron deficiency. *New Zealand Dental Journal*, 65(302), 258–261, 2008.