

## Original Article

# Modified Pedicle Subepithelial Connective Tissue Graft for Interdental Papillary Reconstruction Around Delayed Implants in The Esthetic Zone: A CASE SERIES TRAIL

Ahmed Sadek Mohamed<sup>1</sup>, Weam EL Battway<sup>1</sup>, Samar EL Khouly<sup>1</sup>

<sup>1</sup>Department of Periodontology, Faculty of Dentistry, Cairo University.

Email: ahmedsoraka77@gmail.com

Submitted: 14-12-2024

Accepted: 11-3-2024

## Abstract

**Aim:** This study aimed to evaluate the effect of a modified pedicle subepithelial connective tissue graft in creating anatomical papilla around one-stage delayed implant in the esthetic zone to establish better esthetics.

**Subjects and methods:** Ten patients with a missing upper tooth in the esthetic zone were indicated for delayed implant placement where modified pedicle subepithelial connective tissue graft for papilla reconstruction was performed. All patients were assessed for the outcomes: papilla height, pink esthetic score and patient satisfaction obtained at different intervals (baseline, 3, and 6 months) and subjected to statistical analysis.

**Results:** Mesial papilla height showed statistically significant increase between baseline, 3 and 6 months with no statistically significant difference between 3 and 6 months. The distal papilla showed no statistically significant change between baseline and 3 months but there was statistically significant increase between baseline and 6 months. Regarding PES there was a statistically significant increase in value after 6 months in comparison to baseline..

**Conclusion:** The modified pedicle connective tissue graft showed promising results in papilla reconstruction and provided more esthetic outcomes around delayed implants.

**Keywords:** Delayed implant, subepithelial connective tissue graft, anatomical papilla, pedicle graft.

## Introduction

Dental implants have become a day-to-day procedure in the dental office. Restoration of missing teeth alone should not be considered as a success of an implant procedure. Restoration of lost gingival tissues and creation of a gingiva similar to that in

natural dentition should be considered as the ultimate success of an implant (**Ibrahim, Helaly and Ahmed, 2021**). Therefore, establishing a soft tissue contour with intact interproximal papillae around implant retained restoration is challenging and failure to achieve these harmonious relationships of soft tissue around implant may lead to unaesthetic

appearance (Avila-Ortiz et al., 2014). A recent systematic review concluded that gaining sufficient gingival thickness could promote greater stability of interproximal marginal bone levels (Thoma et al., 2014). In a series of investigations, it was demonstrated that a thin peri-implant mucosa, as measured from the bone crest in an apico-coronal direction, also referred to as the supracrestal tissue height, is associated with greater marginal bone loss than a thick tissue phenotype (Linkevicius et al., 2015).

Different techniques to increase the peri-implant soft tissue phenotype has been extensively investigated (Avila-Ortiz et al., 2014). Autogenous soft tissue grafts either the free gingival graft or connective tissue graft were the first grafting approaches evaluated because of the satisfactory results shown around the natural dentition (Zucchelli et al., 2010). However, because of the decreased vascular bed around dental implants when compared to natural teeth, the pedicle palatal connective tissue flap technique was utilized to augment the soft tissue around dental implants.

This pedicle flaps aided in improving the vascularity of the connective tissue graft, reducing any possible shrinkage and thus enhancing the chance for its survival (Peñarrocha, García-Mira and Martinez, 2005).

Various soft-tissue surgical procedures were introduced in an attempt to re-create the papillae around implants (Gupta, Deo and Williams, 2012). Therefore, this study was conducted to evaluate the effect of modified pedicle subepithelial connective tissue flap on interdental papillary reconstruction around delayed implants.

### **Subjects and Methods**

Ten patients were selected from the out-patient clinic of Periodontology department, Faculty of dentistry, Cairo University. All patients were having 10 missing teeth in the upper esthetic zone, requiring its replacement by a dental implant.

All participants who volunteered to enroll

were given a thorough explanation of the process before being asked to sign a written informed consent form. Patients were assigned into the single test procedure, including modified pedicle subepithelial connective tissue graft for papilla reconstruction around delayed implant in esthetic zone.

Inclusion criteria: Patients of 18 years or older, with sufficient bone width and height for implant placement, adequate mesiodistal width and inter-arch space for placement of a delayed implant, periodontally healthy adjacent teeth, and cooperative patients who will comply to follow up visits. Exclusion criteria are pregnant and lactating females, smokers (Obeid and Bercy, 2000), patients with any systemic condition that may affect wound healing and the outcomes of the surgical procedure as uncontrolled diabetes or osteoporosis (Tandara and Mustoe, 2004), handicapped and mentally retarded patients who might be non-compliant to the postsurgical instructions and follow-up visits, and patients undergoing radiotherapy (Shugaa-Addin et al., 2016).

A preoperative cone beam computed tomography (CBCT) was performed for each patient prior to the surgery. From the obtained CBCT the implant length and diameter were determined, in addition to determining the underlying bone condition. Participants received phase I therapy where scaling and debridement were performed using ultrasonic scalers and 0.12% chlorhexidine mouthwash were given.

The papilla height (primary outcome) was determined by using a periodontal probe measuring from the reference line to the maximum papilla height mesially and distally (Grossberg, 2001). The reference line was drawn over the preoperative photograph from the most apical points of gingival margins on the two adjacent teeth mesial and distal to the edentulous area **figure (1, A)**. The papilla height was measured mesially and distally to the edentulous area at baseline.

Local anesthesia (40 mg/ml + 0.01mg/ml. Artinibsa, Inibsa dental Co., Japan) was applied to the edentulous area. A cresta

incision were done using blade 15C (Hu-Friedy, Chicago, USA). The papillae of the incision was made at the end of the horizontal incision and extended to the alveolar mucosa to allow the coronal advancement of the flap **figure (1, C)**. Preparation of the implant site, **(Stiévenart and Malevez, 2010)** was initiated by raising a buccal flap via a crestal incision on the ridge bisecting the existing keratinized mucosa and two beveled vertical releasing incisions extending to the vestibule. The incisions were done using blade 15C. The distant papillae of the adjacent teeth were not included in the flap design, while the papillae related to the edentulous site were involved to enhance manageability and handling of the flap and the pedicle connective tissue (Giraddi and Saifi, 2017). A full thickness flap was raised buccally exposing the edentulous ridge of the implant site **figure (1, D)**. The site where the implant was to be placed was determined via a precise placement of the pilot drill. After pilot drill application, the osteotomy was prepared with sequential drilling of corresponding sizes of parallel drills till reaching the desired implant diameter.

After drilling of the implant site, a parallel pin was inserted to ensure parallelism **figure (1, E)**. The implant was placed in the osteotomy prepared by means of an insertion device. The implant insertion (SOLVO UK IMPLANT CO.LTD) was applied manually by torque wrench and the implant neck was positioned flushing with the crestal bone level **figure (1, F)**. Then the healing abutment extension of the implant was placed in such a way that the head of the implant protruded about 2 to 3 mm from the bone crest **(Faraji and Van Zyl, 2016)**.

Local anesthesia was applied at the palatal donor site, with particular care not to distort the tissue volume. The palatal pedicle subepithelial connective tissue graft was harvested by a single palatal incision approach stopping the incision a few millimeters distal to the implant site **figure (1, G)**. The width of the graft was calculated to match the mesio-distal

adjacent teeth were not included in the flap design **figure (1, B)**. A vertical releasing size of the lateral implant space. The pedicle graft was then dissected at the coronal, distal and apical aspects, leaving the mesial side attached **(Faraji and Van Zyl, 2016)**. A tunnel was created under the palatal mucosa, connecting the donor site to the implant area. A suture was used at the distal end of the pedicle connective tissue graft to aid in sliding it under the created tunnel and into the facial aspect **figure (1, H) (Romanos, Geurs and Abou-Arraj, 2013)**.

Then the distal end of the pedicle connective tissue graft was divided into two parts by a surgical knife. This resulted in each connective tissue part being placed interproximally between the healing abutment and the adjacent teeth **figure (1, I)**. Once the pedicle connective tissue graft was adapted, the bifid part of the graft was then placed around the abutment and sutured using resorbable suture 5/0 on the facial aspect. Then the flap and the palatal donor site were sutured using resorbable suture 5/0 (AssuCryl, Assut sutures, Switzerland) **figure (1, J) (Faraji and Van Zyl, 2016)**.

Each participant was instructed to use soft diet for the first 5 days, and chlorhexidine mouthwash (Hexitol, ADCO, Pharma, Co, Cairo, Egypt) to rinse twice daily for 14 days **(Solderer et al., 2019)**. Ibuprofen 400mg (Kahira Pharmaceuticals, Egypt) was prescribed for the patient twice daily for three days **(Alissa et al., 2009)**. Amoxicillin/clavulanic acid 1gm (Misr Co. for Pharmaceutical Industries, Egypt) was prescribed for the patient twice daily for one week **(Feng (Feng, Lin and He, 2017)**.

Sutures were removed after 14 days and a proper temporary crown was placed **(Pippi, 2017)** and each patient was followed up after 1 week, 2 weeks, 1 month, 3 months, and 6 months postoperatively. At 3 months after recording the papilla height, a final zirconia crown was done for each patient. The contact areas of the crown were designed so that the

stand 5 mm away from the alveolar crest to avoid any black triangles (Tarnow, Magner and Fletcher, 1992). After 6 months, all the records were taken as papilla height (mesial and distal), pink esthetic score and patient satisfaction.

**Mesial and distal papilla height:**

Papilla height was measured mesially and distally at 3, 6 months. A reference line was drawn over the preoperative photograph from the most apical points of gingival margins on the two adjacent teeth mesial and distal to the edentulous area. The mesial and distal papilla height was determined by using a periodontal probe measuring the distance from reference line to contact point of crown. **Figure (1, K&L).**

**Pink esthetic score: (PES) (secondary outcomes)**

The PES was measured at baseline, 3 months after 6 months postoperatively. PES was based on seven variables: mesial papilla, distal papilla, soft-tissue level, soft tissue contour, alveolar process deficiency, soft-tissue color and texture (Fürhauser *et al.*, 2005). Each variable was assessed with a 2-1-0 score, with 2 being the best and 0 being the poorest score.

**Patient satisfaction (Kivak *et al.*, 1984): (secondary outcomes):**

A 3-item questionnaire was given to the patients to be answered using a 7-point answer scale for assessing their satisfaction with the whole procedure and the results of the procedure performed. Three questions were posed in questionnaires and asked to ascertain patients' satisfaction with the outcomes of surgery. These questions were all answered by the patients in paper and pencil form, using a 7-point response scale: very likely (or very satisfied) = 7; not at all likely (or not at all satisfied) = 1.

**Results**

Statistical analysis was performed using IBM (NY: IBM Corp. USA) Statistical Package for Social Sciences SPSS for Windows

version 26.

The comparisons between different time points were done using paired t-test and the mean difference along with 95% confidence interval (CI) were reported. For non-normally distributed data, descriptive statistics were presented as mean  $\pm$  SD, median and range and comparisons between different time points were done using Wilcoxon signed-rank test.

The mean ( $\pm$ SD) value of the distal papilla height at baseline was 2.30 ( $\pm$ 0.17) mm. After 3 months, distal papilla height increased to 2.50 ( $\pm$ 0.78) mm but with no statistically significant difference from baseline (P-value=0.399) with mean increase of 0.20 mm and 95% CI [-0.31, 0.71]. After 6 months, the mean ( $\pm$ SD) value was 2.80 ( $\pm$ 0.79) mm and the difference from baseline was statistically significant (P-value=0.004) with a mean increase of 0.50 mm and 95% CI [0.21, 0.79]. However, there was no statistically significant difference between 3 and 6 months (P-value=0.279) (Table 1).

Mesial papilla showed a mean ( $\pm$ SD) increase of 0.50 ( $\pm$ 0.58) mm from baseline to 3 months which corresponded to a mean ( $\pm$ SD) percentage increase of 24.50 ( $\pm$ 29.18) %. While the mm change from baseline to 6 months showed a mean ( $\pm$ SD) increase 0.55 ( $\pm$ 0.60) mm which corresponded to a mean ( $\pm$ SD) increase of 28.50 ( $\pm$ 29.77) %. The mean ( $\pm$ SD) mm difference between 3 and 6 months was 0.05 ( $\pm$ 0.86) mm which was corresponding to mean ( $\pm$ SD) % change of 9.12 ( $\pm$ 40.02) (Table 1).

The mean ( $\pm$ SD) value of the distal papilla height at baseline was 2.30 ( $\pm$ 0.17) mm. After 3 months, distal papilla height increased to 2.50 ( $\pm$ 0.78) mm but with no statistically significant difference from baseline (P-value=0.399) with mean increase of 0.20 mm and 95% CI [-0.31, 0.71]. After 6 months, the mean ( $\pm$ SD) value was 2.80 ( $\pm$ 0.79) mm and the difference from baseline was statistically significant (P-value=0.004) with a mean increase of 0.50 mm and 95% CI [0.21, 0.79]. However, there was no statistically significant

difference between 3 and 6 months (P-value=0.279) (Table 1).

(Table3)

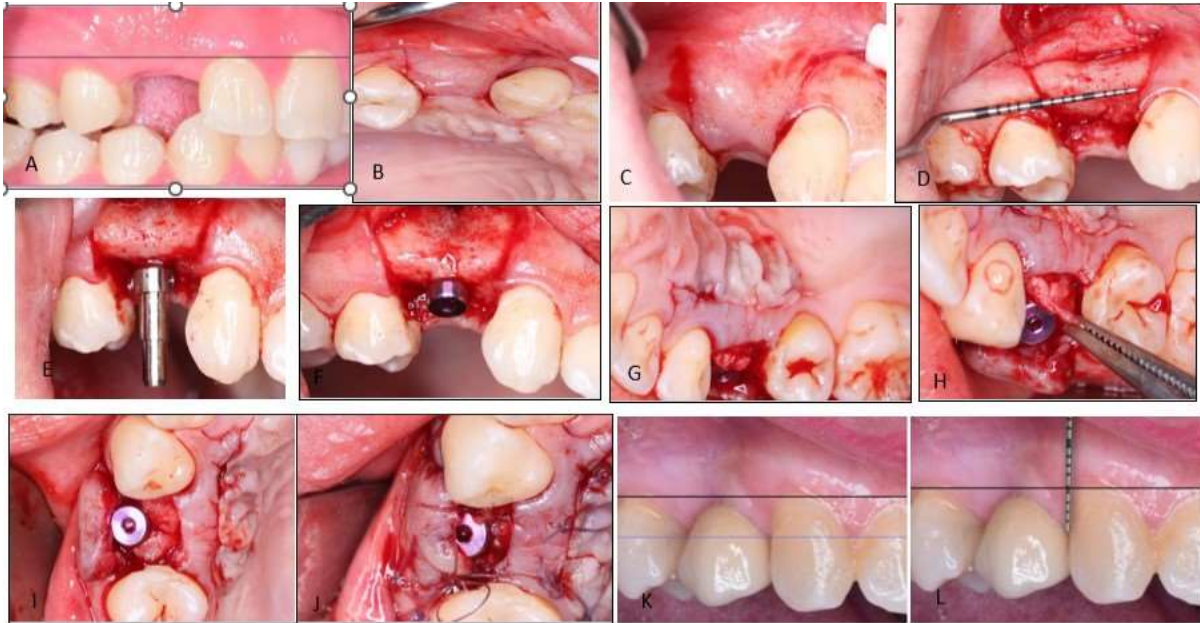
Distal papilla height from baseline to 3 months increased by 0.20 ( $\pm 0.71$ ) which corresponded to mean ( $\pm$ SD) 11.00 ( $\pm 39.76$ ) % when expressed in percentage. While the mean ( $\pm$ SD) mm change from baseline to 6 months increased by 0.50 ( $\pm 0.41$ ) mm and 20.83 ( $\pm 22.02$ ) % when expressed in percentage. While the mm difference between 3 and 6 months showed a mean ( $\pm$ SD) increase of 0.30 ( $\pm 0.82$ ) mm corresponding to 18.40 ( $\pm 41.41$ ) (Table 1).

PES had a mean ( $\pm$ SD) of 12.16 ( $\pm 1.13$ ) with a median (range) of 12.65 (11.25-13.00). After 3 months, the mean ( $\pm$ SD) was 13.85 ( $\pm 0.22$ ) with median (range) of 14 (13.65-14.00) with a statistically significant increase (P-value =0.005) from baseline till 3 months interval.

While at 6 months the mean ( $\pm$ SD) was 13.17 ( $\pm 0.65$ ) with median (range) of 13.40 (12.83- 13.50). Similarly, there was a statistically significant difference between baseline and 6 months value (P-value =0.005) (Table 2).

After 3 months, there was a mean ( $\pm$ SD) increase in PES by 1.69 ( $\pm 0.96$ ) which corresponded to a mean ( $\pm$ SD) percentage increase by 14.74 ( $\pm 10.27$ ) %. After 6 months, the mean ( $\pm$ SD) increase in PES was 1.01 ( $\pm 0.56$ ) corresponding to 8.76 ( $\pm 5.68$ ) % on percentage basis. When the values of 3 months were compared to 6 months, there was a decrease in PES after 6 months as the mean ( $\pm$ SD) difference was -0.68 ( $\pm 0.52$ ) corresponding to percentage of -4.94 ( $\pm 3.81$ ) % (Table 2).

When the patients were asked the 3-item questionnaire in the patient satisfaction, the mean ( $\pm$ SD) values were 6.80 ( $\pm 0.42$ ) with median 7.00 and range 6.75,7.00. The percentage showed that 60% of patients said yes on the first question (Q1) and 90% of the patients said yes on the second question (Q2) while on the third question (Q3) 80% said yes



**Figure 1: A. Intra-oral photograph showing a missing lateral with a reference line connecting the gingival margins of adjacent teeth. B. Intra-oral photograph showing the crestal and two vertical incisions. C. intra-oral photograph showing the flap design. D. Intra-oral photograph showing the process of determining the precise site of drilling. E. Intra-oral photograph showing drilling of implant. F. Intra-oral photograph showing healing abutment extended about 2 to 3mm G. Intra-oral photograph showing a single palatal incision for harvesting connective tissue graft. H. Intra-oral photograph showing a tunnel created to transfer the connective tissue graft to the implant area. I. Intra-oral photograph showing the bifid part of the pedicle connective tissue graft placed around the abutment. J. Intra-oral photograph showing suturing of the surgical site.K. Intra-oral photograph showing papilla height at 3 months follow up. L. Intra-oral photograph showing distal papilla height at 6 months follow up.**

Table (1): Papilla height: (Primary outcome)

	Follow up	Mean ( $\pm$ SD)	P-value vs. baseline	95% confidence interval
Mesial papilla	T0	2.20 ( $\pm$ 0.42)	NA	
	T1	2.70 ( $\pm$ 0.63)	0.023*	0.50 [0.09, 0.91]
	T2	2.75 ( $\pm$ 0.49)	0.017*	0.55 [0.12, 0.98]
Change in mesial papilla (mm)	T0-T1	0.50 ( $\pm$ 0.58)		1.00, 2.25
	T0-T2	0.55 ( $\pm$ 0.60)		0.50, 1.58
	T1-T2	0.05 ( $\pm$ 0.86)		-0.83, -0.50
Change in mesial papilla %	T0-T1	24.50 ( $\pm$ 29.18)		3.63, 45.37
	T0-T2	28.50 ( $\pm$ 29.77)		7.21, 49.79
	T1-T2	9.12 ( $\pm$ 40.02)		-19.51, 37.75
Distal papilla	T0	2.30 ( $\pm$ 0.17)	NA	
	T1	2.50 ( $\pm$ 0.78)	0.399*	0.20 [-0.31 – 0.71]
	T2	2.80 ( $\pm$ 0.79)	0.004*	0.50 [0.21 – 0.79]
Change in distal papilla (mm)	T0-T1	0.20 ( $\pm$ 0.71)		-0.31, 0.71
	T0-T2	0.50 ( $\pm$ 0.41)		0.21, 0.79
	T1-T2	0.30 ( $\pm$ 0.82)		-0.29, 0.89
Change in distal papilla %	T0-T1	11.00 ( $\pm$ 39.76)		-17.44, 39.44
	T0-T2	20.83 ( $\pm$ 22.02)		5.08, 36.58
	T1-T2	18.40 ( $\pm$ 41.41)		-11.22, 48.03

**Table (2): Pink Esthetic score (PES) at different time intervals (secondary outcome)**

	Follow up	Mean ( $\pm$ SD)	P-value	Median (Interquartile range)
Pink esthetic score	T0	12.16 ( $\pm$ 1.13)	NA	12.65(11.25-13.00)
	T1	13.85 ( $\pm$ 0.22)	0.005*	14.00(13.65-14.00)
	T2	13.17 ( $\pm$ 0.65)	0.005*	13.40(12.83-13.50)
Change in PES	T0-T1 (mm)	1.69 ( $\pm$ 0.96)		1.25 (1.00-2.25)
	T0-T1 (%)	14.74 ( $\pm$ 10.27)		9.94 (7.69-20.19)
	T0-T6 (mm)	1.01 ( $\pm$ 0.56)		1.00 (0.50-1.58)
	T0-T6 (%)	8.76 ( $\pm$ 5.68)		7.91 (3.85-14.07)
	T1-T2 (mm)	-0.68 ( $\pm$ 0.52)		-0.50 (-0.83- -0.50)
	T1-T2 (%)	-4.94 ( $\pm$ 3.81)		-3.60 (-5.97- -3.57)

**Table (3): Patient Satisfaction (secondary outcome)**

			Number	Percentage
Questions	Q1	Yes	6	60
		No	4	40
	Q2	Yes	9	90
		No	1	10
	Q3	Yes	8	80
		No	2	20

### Discussion

To explore better methods for reconstructing interdental papilla, the current study aiming to evaluate the effect of a modified pedicle subepithelial connective tissue graft on the mesial and distal papilla height and the pink esthetic score for papilla reconstruction around one-stage delayed implant in the esthetic zone to establish better esthetics. This pedicle graft

contributes to accelerating blood supply promoting early initial healing with highly predictable outcomes. The keystone is providing sufficient connective tissue with adequate blood supply through a pedicle connective tissue graft. Compared with free grafts, the blood supply of the pedicle graft is retained at the donor site, which is a major advantage. In addition, the tunneling procedure increased the stability at the recipient site. This method demonstrated minimal postoperative



morbidity, as well as offering soft tissue closure at both the donor and recipient sites (**Faraji and Van Zyl, 2016**).

In this modified technique a pedicle connective tissue graft was used, and the distal end of the pedicle graft was divided into two parts, creating a bifid. The bifid part of the graft was then placed around the abutment and sutured on the facial aspect. The purpose of this procedure was to increase the amount of soft tissue around the abutment, maintaining its stability.

The fact that limited evidence exists in the literature for this exact technique of papilla reconstruction around delayed implants hindered the possibility of comparing the results of this current study to other clinical trials. Therefore, comparisons to similar trials of papilla reconstruction were carried out to shed light on the efficacy of this technique.

Despite the increase in the papilla height that was observed in this study, this did not agree with the study of **Grossberg**, who used midline double pedicle flap between two implants, and only 4 out of 12 patients showed an increase in the height of the papilla after abutments connection while the remaining 7 patients showed an actual loss in the papilla height (**Grossberg, 2001**). His study had an average loss of 0.4 mm in the height of the Interimplant papilla, with a range between 2.3 mm of gain and 2.0 mm loss of soft tissue height. However, this difference could be attributed to the different surgical techniques where he performed a midline double pedicle flap which was mobilized mesially and distally. In addition, this technique tried to augment the papilla between implants while this study augmented the papillae between the implant and the adjacent natural teeth, hence the distance between crestal alveolar bone and contact point was more preserved.

**De Castro Pinto et al, (De Castro Pinto et al.)** showed comparable results in their case report that evaluated the effect of pedicle SCTG combined with coronally advanced flap for restoring missing papilla around natural teeth. After 4 months, the therapeutic measures

yielded satisfactory increase of the interdental papilla and more favorable esthetics. The distance between the contact point and the tip of the interdental papilla decreased from 2.5 mm to 0.5 mm with 80% reduction. Despite the difference in the periodontium environment between natural teeth and dental implants, yet the effectiveness of the pedicle connective tissue grafts showing promising results in papilla reconstruction purpose (**De Castro Pinto et al., 2010**).

#### **Conclusion:**

1) The modified pedicle connective tissue graft for papilla reconstruction around delayed implant could be considered as a successful technique for maintaining and reconstructing the papilla height.

2) The modified pedicle connective tissue graft is sensitive technique and require surgical experience with clinical skills.

#### **Conflict of Interest:**

The authors declare no conflict of interest.

#### **Funding:**

This research received no specific grant from any funding agency in the public, commercial, or not-for-profit sectors

#### **Ethics:**

This study protocol was approved by the ethical committee of the faculty of dentistry- Cairo university on: April 2020, approval number 14420

#### **References**

1. Alissa, R., Sakka, S., Oliver, R., Horner, K., Esposito, M., Worthington, H. V. and Coulthard, P. (2009) 'Influence of ibuprofen on bone healing around dental implants: a randomised double-blind placebo-controlled

2. clinical study', *Eur J Oral Implantol*, 2(3), pp. 185-199.
3. Avila-Ortiz, G., Elangovan, S., Kramer, K. W. O., Blanchette, D. and Dawson, D. V. (2014) 'Effect of alveolar ridge preservation after tooth extraction: A systematic review and meta-analysis', *Journal of Dental Research*, 93(10), pp. 950-958.
4. De Castro Pinto, R. C. N., Colombini, B. L., Ishikiriama, S. K., Chambrone, L., Pustiglioni, F. E. and Romito, G. A. (2010) 'The subepithelial connective tissue pedicle graft combined with the coronally advanced flap for restoring missing papilla: A report of two cases', *Quintessence International*, 41(3).
5. Faraji, M. and Van Zyl, A. (2016) 'Surgical reconstruction of lost papilla around implant with a modified technique: A case report', *Journal of Advanced Periodontology & Implant Dentistry*, 8(2), pp. 67-72.
6. Feng, Y., Lin, M. and He, F. (2017) 'The use of antibiotics in dental implantology', *Zhonghua kou qiang yi xue za zhi= Zhonghua kouqiang yixue zazhi= Chinese journal of stomatology*, 52(5), pp. 320-323.
7. Fürhauser, R., Florescu, D., Benesch, T., Haas, R., Mailath, G. and Watzek, G. (2005) 'Evaluation of soft tissue around single-tooth implant crowns: the pink esthetic score', *Clinical oral implants research*, 16(6), pp. 639-644.
8. Giraddi, G. B. and Saifi, A. M. (2017) 'Bone ring augmentation around immediate implants: a clinical and radiographic study', *Annals of Maxillofacial Surgery*, 7(1), pp. 92.
9. Grossberg, D. E. (2001) 'Interimplant papilla reconstruction: assessment of soft tissue changes and results of 12 consecutive cases', *Journal of periodontology*, 72(7), pp. 958-962.
10. Gupta, S., Deo, V. and Williams, C. (2012) 'Interproximal papillae reconstruction around implant using subepithelial connective tissue graft in maxillary anterior region: a case series', *Journal of oral & maxillofacial research*, 3(2).
11. Ibrahim, R. E. H. M., Helaly, M. O. and Ahmed, E. M. A. (2021) 'Assessment of Brushing Techniques in School Children and Its Association with Dental Caries, Omdurman, 2019', *International Journal of Dentistry*, 2021.
12. Kiyak, H. A., Hohl, T., West, R. A. and McNeill, R. W. (1984) 'Psychologic changes in orthognathic surgery patients: a 24-month follow up', *Journal of Oral and Maxillofacial Surgery*, 42(8), pp. 506-512.
13. Linkevicius, T., Puisys, A., Steigmann, M., Vindasiute, E. and Linkeviciene, L. (2015) 'Influence of vertical soft tissue thickness on crestal bone changes around implants with platform switching: a comparative clinical study', *Clinical implant dentistry and related research*, 17(6), pp. 1228-1236.
14. Obeid, P. and Bercy, P. (2000) 'Effects of smoking on periodontal health: a review', *Advances in therapy*, 17(5), pp. 230-237.
15. Peñarrocha, M., García-Mira, B. and Martinez, O. (2005) 'Localized vertical maxillary ridge preservation using bone cores and a rotated palatal flap', *International Journal of Oral & Maxillofacial Implants*, 20(1).
16. Pippi, R. (2017) 'Post-surgical clinical monitoring of soft tissue wound healing in periodontal and implant surgery', *International journal of medical sciences*, 14(8), pp. 721.
17. Romanos, A. H., Geurs, N. C. and Abou-Arraj, R. V. (2013) 'Pedicle Connective Tissue Graft With Novel Palatal Tunneling', *Clinical Advances in Periodontics*, 3(4), pp. 191-198.
18. Shugaa-Addin, B., Al-Shamiri, H.-M., Al-Maweri, S. and Tarakji, B. (2016) 'The effect of radiotherapy on survival

19. of dental implants in head and neck cancer patients', *Journal of clinical and experimental dentistry*, 8(2), pp. e194.
20. Solderer, A., Kaufmann, M., Hofer, D., Wiedemeier, D., Attin, T. and Schmidlin, P. R. (2019) 'Efficacy of chlorhexidine rinses after periodontal or implant surgery: a systematic review', *Clinical oral investigations*, 23(1), pp. 21-32.
21. Stiévenart, M. and Malevez, C. (2010) 'Rehabilitation of totally atrophied maxilla by means of four zygomatic implants and fixed prosthesis: a 6–40-month follow-up', *International journal of oral and maxillofacial surgery*, 39(4), pp. 358-363.
22. Tandara, A. A. and Mustoe, T. A. (2004) 'Oxygen in wound healing—more than a nutrient', *World journal of surgery*, 28(3), pp. 294-300.
23. Tarnow, D. P., Magner, A. W. and Fletcher, P. (1992) 'The effect of the distance from the contact point to the crest of bone on the presence or absence of the interproximal dental papilla', *Journal of periodontology*, 63(12), pp. 995-996.
24. Thoma, D. S., Buranawat, B., Hämmerle, C. H., Held, U. and Jung, R. E. (2014) 'Efficacy of soft tissue augmentation around dental implants and in partially edentulous areas: a systematic review', *Journal of clinical periodontology*, 41, pp. S77-S91.
25. Zucchelli, G., Mele, M., Stefanini, M., Mazzotti, C., Marzadori, M., Montebugnoli, L., Stefanini, M. and Mazzotti, C. (2010) 'Patient morbidity and root coverage outcome after subepithelial connective tissue and de-epithelialized grafts : a comparative randomized- controlled clinical trial', pp. 728-738.