

Original Article

Clinical and Cost-effectiveness of Allium sativum oil versus Mineral Trioxide Aggregate in primary molars pulpotomy in a group of Egyptian children: A Randomized Clinical Pilot Study.

Lobna Magdy Mahmoud El-Bannan^{1,2}, Mahmoud Eid², Ahmed El-Khadem²

¹B.D.S Modern Sciences and Arts university (M.S.A), Egypt.

² Pediatric Dentistry and Dental Public Health Department, Faculty of Dentistry, Cairo University

Email: Lobna.mahmoud@dentistry.cu.edu.eg

Submitted: 21-10-2023

Accepted: 3-1-2024

Abstract

Aim: To determine and compare the clinical and cost-effectiveness (CE) of Allium Sativum oil (ASO) versus Mineral trioxide aggregate (MTA) in primary molars pulpotomy in a group of Egyptian children

Subjects and methods: This is a randomised clinical pilot study with two arms, parallel groups, and allocation blinded. Twenty-six children (n=52) participated in this clinical trial with maxillary and mandibular second primary molars indicated for vital pulpotomy and were randomly allocated into two equal groups. Group (I): pulpotomy using ASO, and Group (II): using MTA as pulpotomy agents. The follow-up period was one year, and the primary outcome was evaluating clinical effectiveness for both groups through the help of predetermined criteria during the follow-up period and according to the participant timeline. The secondary outcome was CE, measured using incremental CE ratio (ICER) and average CE ratio (ACER).

Results: The relative risk of radiographic failure signs of the ASO group over the MTA group was (1.3) (95% CI 0.89:1.7) after 12 months. MTA had a higher (ACER) (67.00) than ASO (39.55).

Conclusion: Allium Sativum oil is non-inferior to Mineral trioxide aggregate regarding clinical efficacy. ASO has a lower average cost-effectiveness ratio than MTA.

Keywords: Cost-effectiveness, Allium Sativum, Mineral trioxide aggregate, Pulpotomy.

Introduction

One major challenge in pediatric dentistry is selecting the optimum pulp medication with the required properties, for example, sustaining the vitality of the remaining undamaged pulp and boosting its healing (Gupta *et al.*, 2018; Kahvand *et al.*, 2019). In pediatric dentistry, keeping primary teeth functioning is of great concern. In primary

teeth, the ideal pulpotomy medicament would be bactericidal, biocompatible, promote root pulp healing, and be compatible with the natural process of root resorption (Ansari *et al.*, 2018; Kahvand *et al.*, 2019).

Mineral trioxide aggregate (MTA) is an extremely effective pulpotomy material. It is biocompatible, non-toxic, and can create dentin bridges with a 100% clinical and

radiographic success rate. However, it has several limitations, such as the fact that it is not cost-effective and hence out of reach for part of the general public, because the overall treatment cost is incompatible with pricing established by social security systems in many countries (Kalra *et al.*, 2017; Madan *et al.*, 2020).

Nowadays, a shift toward natural products as medicinal plants is extensively studied. *Allium Sativum* (garlic) is being studied and researched comprehensively. Apart from its cost-effectiveness (CE) as compared to MTA, the impact of garlic oil on dental pulp wound healing, antibacterial activity, and anti-inflammatory qualities make *Allium Sativum* oil (ASO) a therapeutically promising material. Garlic extracts have an antioxidant effect due to their high polyphenol and flavonoid content. Growth inhibition of both gram-positive and gram-negative bacteria has been recorded (Casella *et al.*, 2013; Mohammad and Baroudi, 2015). To illustrate the ability of innovative natural products to substitute higher-cost pharmacological materials while achieving the same good clinical and radiographic long-term results, treatment with a safe, natural product, such as *Allium Sativum* (AS) oil, is advocated (Subramanyam and Somasundaram, 2017; Madan *et al.*, 2020).

Garlic contains antibacterial and antioxidant properties, helps to regulate the immune system, and can aid in wound healing. In this regard, phytotherapy which employs plants or plant extracts for medical reasons, has made significant progress in recent years (Mohammad *et al.*, 2014; Bhatwalkar *et al.*, 2021). ASO was used in primary teeth pulpotomy resulting in 90% overall higher success than FC (Mohammad *et al.*, 2014). Mohamed and Baroudi discovered that ASO had a greater histological success rate in pulpotomy than FC (Mohammad and Baroudi, 2015).

Rare clinical and CE studies were conducted in the literature comparing ASO versus MTA, so the need for innovative

alternative pulpotomy materials that are therapeutically effective but less expensive than MTA should be investigated (Smâil-Faugeron *et al.*, 2018). The last published trial to evaluate ASO versus MTA in terms of its radiographic and clinical success was a randomised pilot clinical study conducted in 2022, which concluded that ASO showed a better clinical success rate than radiographic one while MTA showed higher overall success after 12-month follow-up (El-Gebaly *et al.*, 2022).

This present trial was centered on the current movement towards mother nature, employing ASO as a pulpotomy natural material, to illustrate the ability of natural products to substitute higher-cost pharmacological materials while achieving the same good clinical and radiographic long-term results.

Subjects and Methods

Study design

This study was a randomised clinical trial: allocation-blinded, 2 arms, parallel-group trial. The operator could not be blinded, while the outcome assessor and the statistician were blinded. The participants were randomised on a 1:1 allocation ratio using computer-generated randomisation to assign which tooth would be either in the control or intervention group to receive one of the following materials: MTA or ASO under the supervision of the co-supervisor Dr. Ahmed El-Khadem.

Sample size

There were no available clinical and cost-effectiveness studies in the literature comparing both treatments to enable calculation, therefore, a pilot study was recommended. The suggested sample size was 20 patients with total number of 40 molars in both groups. To compensate for possible dropouts during follow-up 6 patients were added so, the total sample size was 26 patients with 52 molars in both groups. The research was then approved by the medical biostatistics unit (MBU)

on 11/3/2021, the evidence-based committee on 22-9-2021, and lastly approved by the research ethical committee on 26/10/2021.

Study Setting

This research was conducted in the Pediatric Dentistry & Dental Public Health Department within the Faculty of Dentistry, Cairo University, Egypt. Twenty-six participants were selected from the outpatient clinic with a minimum of two asymptomatic decayed primary second molars. All chosen teeth were randomly separated into two equal groups (MTA group & ASO group). The study was conducted on 52 teeth that were equally and randomly allocated to each test group.

The operator (L.M.) was a post-graduate student with no assistance. Dental unit: Knight dental unit (Midmark Corporation, Patterson Blvd., Ohio, USA). Inclusion criteria involved: healthy cooperative children, aged from 5–7 years, not having antibiotics in the past 14 days, and had at least two carious asymptomatic second primary molars. Exclusion criteria comprised uncooperative immunocompromised children. Also, teeth were excluded from the study if they had clinical or radiographic pathosis to ensure proper dental pulp reaction.

Standardised digital radiography was used at the treatment visit and throughout the follow-up radiographic assessment in this trial using RINN XCP kits for digital sensors. To preserve the same vertical dimension with the same sensor (size 2), the standardised paralleling approach was used. The outcome assessors were two external examiners who did not know the intervention or the control treatment in every radiograph.

Clinical procedure

For both groups, the operator (L.M.) injected anaesthesia, isolated the tooth by rubber dam, removed all caries with a sterile high-speed handpiece using round bur, removed the roof of the pulp chamber using a safe end-cutting bur, and used a spoon excavator for coronal pulp amputation. After washing with saline, one or more sterile cotton pellets moistened with distilled water were put over the pulp stumps, and mild pressure

was given for 5 minutes to achieve hemostasis.

MTA -Angelus white (Angelus, Londrina, PR, Brazil) was used as it is the best available MTA in the Egyptian market. To achieve a putty-like consistency, the substance was made in a 3: 1 powder/liquid ratio according to the manufacturer's specifications, then carried using an amalgam carrier, applied to the pulp chamber, condensed using a suitable condenser, and to allow the MTA paste to solidify, a moistened cotton pellet was put over it. Lastly, Core restoration with glass ionomer filling (GC FUJI IX, Japan). Following that, the stainless-steel crown is cemented using (SDI Riva luting cement, Australia).

The molar pulp stumps are treated for 1 minute with a cotton pellet dampened with Allium sativum oil Captain Company (CAP-PHARM) registration No 952/94 Cairo, Egypt. The access cavity was sealed with a thick combination of Zinc oxide Eugenol (Zinconol, Prevest, India), followed by stainless steel crown cementation using (SDI Riva luting cement, Australia). The whole duration of the follow-up period was 12 months. The clinical and radiographic evaluations were done in accordance with the AAPD recommendations (Dentistry, 2008). According to the participant timeline, clinical assessment during the follow-up period was done one day and three weeks postoperative, while the radiographic assessment was done at 6 and 12 months.

The cost of treatment visits is calculated according to materials prices in the Egyptian market in Egyptian pounds at that time. The cost of follow-up visits including used materials and transportation fees, all added to the total cost.

The researcher performed a clinical examination on the patient to look for the presence and/or absence of pain, gingival inflammation, tooth mobility, swelling, and fistula. Clinical photographs were taken at different intervals as shown in **Figures (1)** and **(2)**. Periapical digital radiographs were used to determine the existence of widened PDL space, radiolucency in the periapical region or furcation area, and external or internal root resorption, as observed in **Figures (3)**, **(4)**, and **(5)**.

Statistical analysis

Categorical data were presented as frequency and percentage values and were analyzed using chi-square and McNemar's tests for inter and intragroup comparisons, respectively. Numerical data were explored for normality by checking the data distribution using the Shapiro-Wilk test. Data were normally distributed, presented as mean and standard deviation values, and analysed using an independent t-test. The average cost-effectiveness ratio (ACER) was calculated based on Bang & Zhao (Bang and Zhao, 2012). The significance level was set at $p \leq 0.05$ within all tests. Statistical analysis was performed with R statistical analysis software version 4.2.3 for Windows (Team, 2023).

Results

Twenty patients (n=40) completed the follow-up and were analysed. As illustrated in **Table (1)**, there was no significant difference between tested groups regarding sex and age. All cases in both groups and intervals were free of any clinical signs. Intergroup comparisons and summary statistics for radiographic signs at 6 months were presented in **Table (2)**.

Intergroup comparisons and summary statistics for radiographic signs at 12 months were described in **Figure (6)**.

After 6 months, 80% of cases showed radiographic signs in the garlic oil group over 45% in the MTA group. At the 12-month follow-up, radiographic signs of the MTA group cases increased to 60%, while the garlic oil group maintained 80% as shown in **Table (3)**.

The cost-effectiveness analysis is presented in **Table (4)** and the incremental cost-effectiveness ratio (ICER) (i.e., the average price needed to save one tooth) was 94.45 L.E.

Clinical photographs of ASO case and MTA case at different intervals are presented in Figures (1) and (2) respectively showing clinical success.

Periapical radiographs for an MTA case and ASO case are presented in Figures (3) and (4) respectively showing radiographic success.

Figure (5) shows Periapical radiographs of an ASO case with root resorption at 6 months and 12 months intervals.

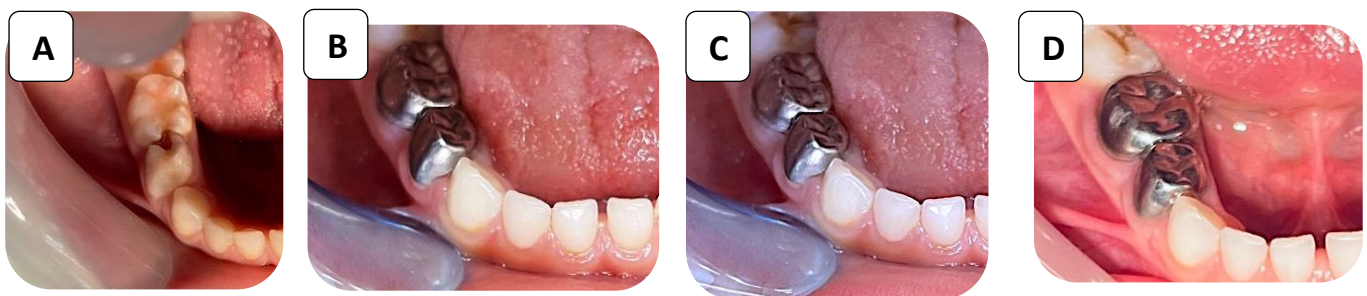


Figure (1): Clinical photographs of ASO case at different intervals; **A:** Pre-operative photograph, **B:** Immediate postoperative photograph, **C:** After 6 months photograph, and **D:** After 12 months photograph.

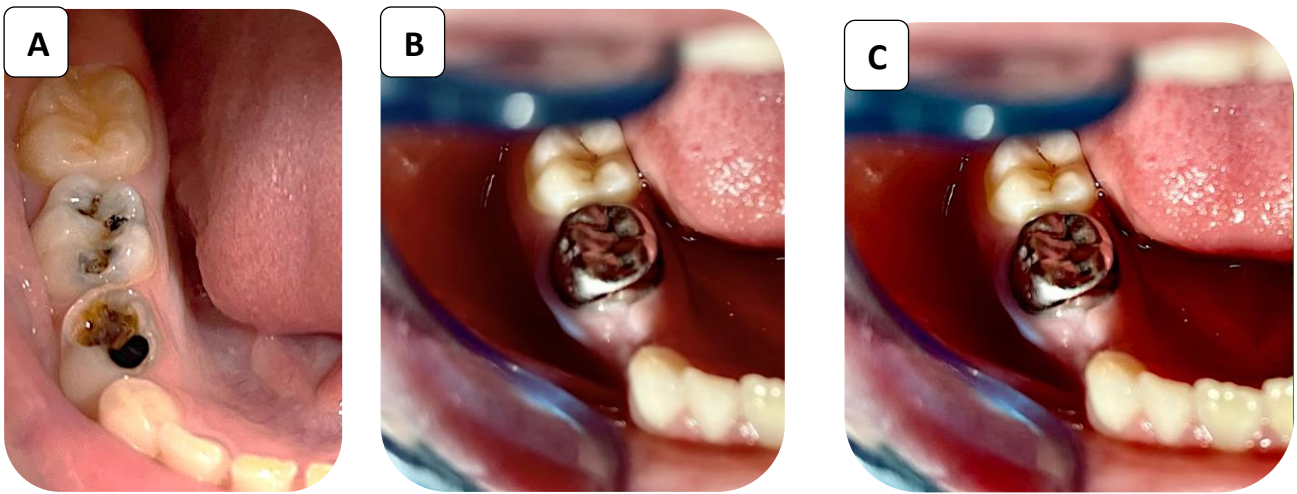


Figure (2): Clinical photographs of MTA case; **A:** Pre-operative photograph, **B:** After 6 months photograph, and **C:** After 12 months photograph.

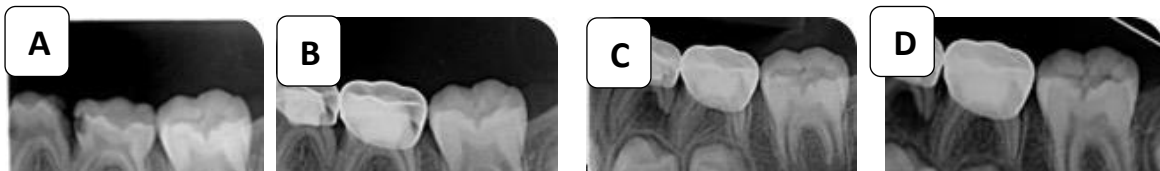


Figure (3): Periapical radiographs of MTA case; **A:** Pre-operative radiograph, **B:** Immediate postoperative radiograph, **C:** After 6 months, radiograph, and **D:** After 12 months radiograph.

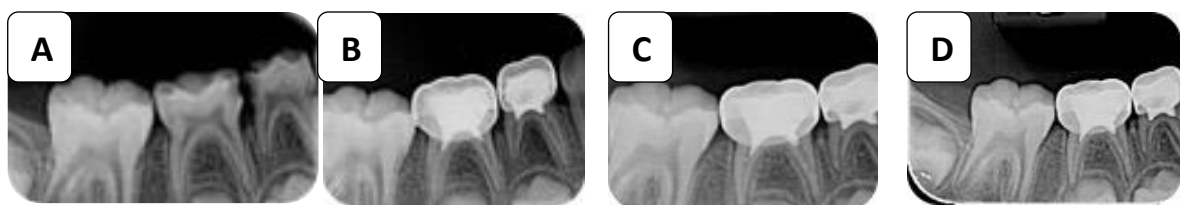

Figure (4): Periapical radiographs of the ASO group (case 1); **A:** Pre-operative radiograph, **B:** Immediate Postoperative radiograph, **C:** After 6 months, radiograph, and **D:** After 12 months, radiograph.

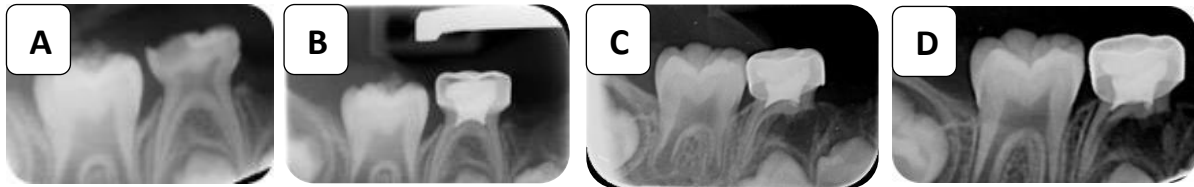


Figure (5): Periapical radiographs of the ASO group (case 2); **A:** Pre-operative radiograph, **B:** Immediate Postoperative radiograph, **C:** After 6 months, radiograph, and **D:** After 12 months, radiograph.

Table (1): Intergroup comparisons and summary statistics for demographic data

Parameter		Garlic oil	MTA	p-value	
Sex	Male	N	10	13	0.523ns
		%	50.0%		
	Female	N	10	7	
		%	50.0%	35.0%	
Age (years)	Mean±SD	6.58±0.67	6.22±0.95	0.174ns	

*, significant ($p \leq 0.05$) ns; non-significant ($p > 0.05$)

Table (2): Intergroup comparisons and summary statistics for radiographic signs at 6 months

Sign	Status		Garlic oil	MTA	RR	p-value
					(95%CI)	
Widened PDL space	No	N	6	15	2.8 (1.99:3.6)	0.004*
		%	30.0%	75.0%		
	Yes	N	14	5		
		%	70.0%	25.0%		
Internal resorption	No	N	11	19	9 (7.04:10.96)	0.003*
		%	55.0%	95.0%		
	Yes	N	9	1		
		%	45.0%	5.0%		
External resorption	No	N	13	20	8 (6.02:9.97)	0.004*
		%	65.0%	100.0%		
	Yes	N	7	0		
		%	35.0%	0.0%		
Periapical radiolucency	No	N	20	20	NA	NA
		%	100.0%	100.0%		
	Yes	N	0	0		
		%	0.0%	0.0%		
Furcation radiolucency	No	N	6	14	2.33 (1.6:3.0)	0.011*
		%	30.0%	70.0%		
	Yes	N	14	6		
		%	70.0%	30.0%		

*; significant ($p \leq 0.05$) ns; non-significant ($p > 0.05$)

Table (3): Inter and intragroup comparisons and summary statistics for radiographic signs

Interval	Radiographic signs		Garlic oil	MTA	Relative risk	p-value
					(95%CI)	
6 months	No	N	4	11	1.7 (1.2:2.2)	0.022*
		%	20.0%	55.0%		
	Yes	N	16	9		
		%	80.0%	45.0%		
12 months	No	N	4	8	1.3 (0.89:1.7)	0.168ns
		%	20.0%	40.0%		
	Yes	N	16	12		
		%	80.0%	60.0%		
p-value			0.149ns	1ns		

*; significant ($p \leq 0.05$) ns; non-significant ($p > 0.05$)

Table (4): Cost-effectiveness analysis

Parameter	Garlic oil	MTA	Incremental cost-effectiveness ratio (ICER)
Average total cost	158.20	536.00	94.45
Effect (successful cases) after 12 months	4	8	
Average cost-effectiveness ratio (ACER)	39.55	67.00	

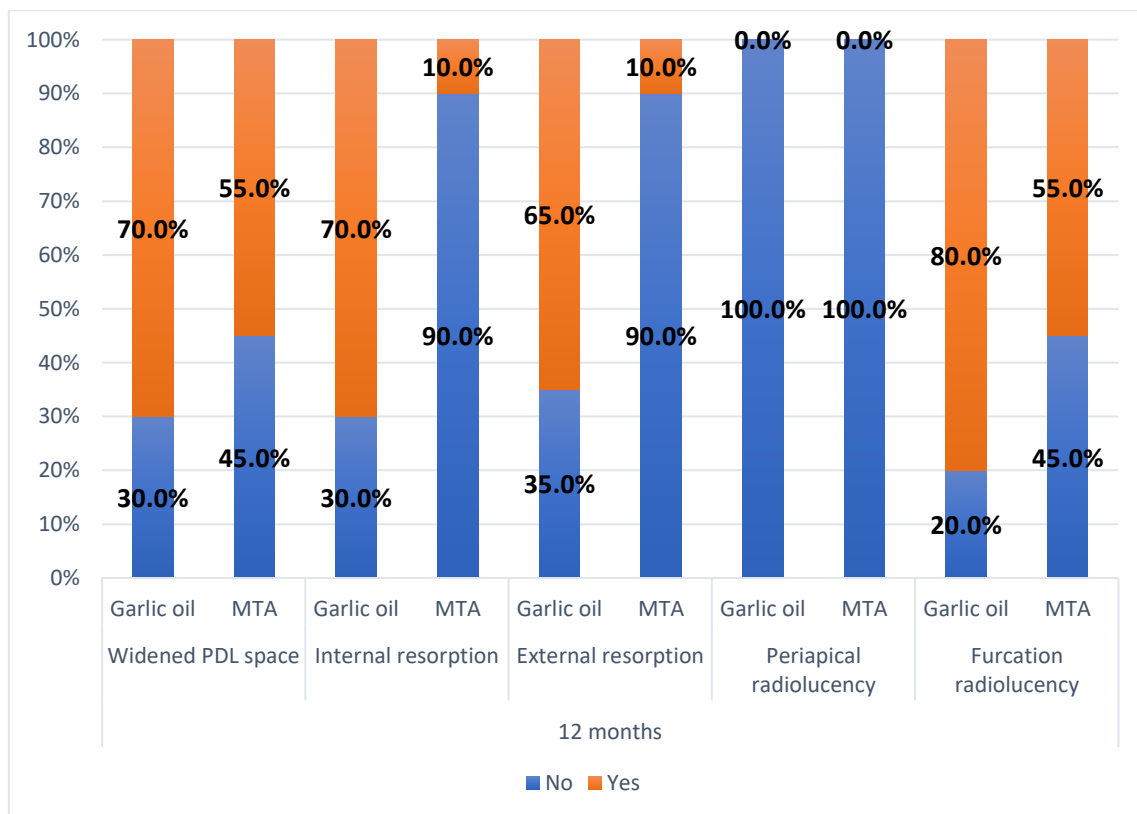


Figure (6): Stacked bar chart showing the percentage of radiographic signs in both groups at 12 months.

Discussion

In recent decades, using natural products has grown dramatically in dentistry. *Allium Sativum* is the scientific name of garlic and it has been vastly used in medical fields. In dentistry, garlic involves using garlic extract as a pulpotomy medicament, mouthwash, and root canal detergent due to its antimicrobial, anti-inflammatory, and antioxidant effects. These beneficial properties of garlic are due to its main components, Allicin and Thiosulfonates (Kahvand *et al.*, 2019; Faghihi *et al.*, 2021).

This trial showed that clinical success in both groups was 100% in agreement with a previous trial conducted in 2021 that assessed the clinical and radiographic evaluation of ASO versus MTA. In this previous trial, clinical success was also 100% in both groups (Faghihi *et al.*, 2021).

However, the results of another clinical trial conducted in 2022 were in contrast with this trial's results, the clinical success rate in the MTA group was 100%, whereas in the ASO group was 93.3% (El-Gebaly *et al.*, 2022). The trial conducted in 2020, showed 100% clinical success in the ASO group in agreement with this trial results (Abirami *et al.*, 2020). In contrast, another trial conducted in 2006, showed only 82.1% clinical success in the MTA group (Neamatollahi and Tajik, 2006). In consonance with this, the absence of any clinical sign on postoperative examinations at every predetermined follow-up visit is an explicit clinical success parameter (Goyal *et al.*, 2016). In this trial, the promising clinical outcome of the ASO group lies in garlic's potent analgesic and anti-inflammatory properties.

In this present trial, the MTA group showed higher radiographic success (55%) after 6 months. After 12 months, MTA radiographic success decreased to (40%) while the ASO group maintained radiographic success (20%) at 6- & 12-month intervals.

Radiographic failure signs in the MTA

group coincide with the trials conducted by Carti and Oznurhan, 2017, Sunitha *et al.*, 2017, and Neamatollahi and Tajik, 2006, reported 96%, 94%, and 69.2%, respectively. In the present study, radiographic success in the MTA group contrasts with a systematic review conducted in 2008, showing that MTA is superior to FC with a 100% radiographic success rate (Fallahinejad Ghajari *et al.*, 2008).

Radiographic failure signs in the ASO group were in agreement with the trial conducted by El-Gebaly *et al.*, 2022, which reported 40% radiographic success, in contrast to the trial conducted by Kahvand *et al.*, 2019, which reported an 80% radiographic success rate. Radiographic failure signs (furcation radiolucency, widened periodontal ligament, periapical radiolucency, internal and external root resorption) are thought to be due to the occurrence of inflammation in the residual pulp (MAGNUSSON, 1970). Chronic pulpal inflammation precedes radiographic failure signs, the disappearance of preodontoblasts & odontoblasts, and pulpal invasion by macrophage-like resorbing cells (Goyal *et al.*, 2016).

MTA showed only 10% (n=2) internal and external resorption at 12 months compared to 70% (n=14) & 65% (n=13), respectively, in the ASO group. This could be explained that Zinc oxide eugenol left in contact with amputated pulp stumps is thought to be the reason for the accentuated internal resorption occurring in the ASO group as stated in 2005, the study showed that irritating properties of eugenol resulted in internal resorption (Huth *et al.*, 2005).

The external resorption is more significant in the ASO group, and this might be due to the release of bacteria and toxins via the apical foramina justifying that MTA is more biocompatible and resistant to bacterial penetration in the periapical areas. The findings were obtained from research done by Caicedo *et al.*, 2006. Furcation radiolucency might be

linked to the diffusion of bacteria and toxins through the accessory canals providing a communication pathway from the floor of the pulp chamber to the furcation area. In this trial, MTA showed fewer signs of furcation radiolucency compared to ASO, and this was mentioned in another study justifying that MTA has the capability of forming hard tissue bridge owing to its superior sealing ability, biocompatibility, alkalinity, and high seal against bacteria (Goyal *et al.*, 2016).

Teeth that showed signs of resorption were kept for further examination because they were asymptomatic with no signs of clinical failure and regarded clinically effective.

In the present investigation, the significant increase in the radiographic signs in the MTA group at 12 months highlights the necessity for a longer follow-up to adequately evaluate the efficacy of each material, as these findings require an extended period to be manifested.

In this trial, justifying all radiographic signs of failure in the ASO group is based on two main parameters, Allicin toxicity of garlic oil and commercially available garlic oil products. Allicin is garlic's most physiologically active sulphur-containing component, it appears as a bright yellow oily liquid with a strong garlic aroma, it is unstable and decomposes at ambient temperature resulting in numerous allyl and methyl sulphide derivatives which are found in crushed garlic plants and garlic essential oils (Batiha *et al.*, 2020; Ezeorba *et al.*, 2022).

Garlic oils on the market are not standardised and lack safety data as each product's final concentration varies by its processing procedure, the amount and composition of sulphides in each garlic oil product change with extraction time and temperature. Therefore, the safety and efficacy of each product in the market must be evaluated independently using pharmacological and

toxicological testing (Amagase H., 2001; Amagase H., 2006).

Although ASO is a recent material with limited trials comparing its clinical effectiveness, it is a promising cost-effective material. Cochrane reviews recommendations in the scope of needed clinical and cost-effectiveness trials with more high-quality research with precise methodological designs and long-term follow-ups are required to determine which medication should be suggested under which economic conditions (Smaïl-Faugeron *et al.*, 2018).

Study Limitations

_A pilot study with relatively small sample size so a study with larger sample size shall be needed.

_The duration of follow-up was 12 months, so a more extended follow-up period may be needed.

_ The composition of garlic oil utilized in this study was not analyzed using gas chromatography-mass spectrometry. GC-MS is an analytical technology, that aims to analyse and quantify the unknown organic components and mixes in every product.

Conclusion

_Both MTA & ASO are clinically effective in primary molars pulpotomy.

_ASO showed a better clinical success rate than the radiographic one.

_ASO has less treatment cost than MTA.

_MTA has a higher average cost-effectiveness ratio, so we can use it in private dental clinics, while ASO can replace it in remote areas and dental public health programs.

Conflict of Interest:

No conflict of interest.

Funding:

This research received no specific grant from any funding agency in the public, commercial, or not-for-profit sectors.

Ethics:

This study protocol was approved by the ethical committee of the faculty of dentistry- Cairo university on: 26/10/2021, approval number: 141021.

References

1. Abirami, K., Ramkumar, H., & Senthil, D. (2020). Clinical and Radiographic Evaluation of the Efficacy of Formocresol, Allium sativum Oil, and Aloe barbadensis Gel as Pulpotomy Medicaments in Primary Molars: A Randomized Controlled Trial. *International Journal of Clinical Pediatric Dentistry*, **13**(5), 518–522. doi:10.5005/jp-journals-10005-1802
2. Ahmad El-Gebaly, N. O., El-Bardissy, A. A.-A., Gawad, R. Y. A. Al, & El-Samad, A. M. A. (2022). Post-operative Pain After Vital Pulpotomy of Primary Molars Using Allium Sativum Oil Versus Mineral Trioxide Aggregate: A Randomized Pilot Clinical Study. *International Journal of Health Sciences*, **(IV)**, 1900–1922. doi:10.53730/ijhs.v6nS4.6482.
3. Amagase, H., Petesch, B.L., Matsuura, H., Kasuga, S. and Itakura, Y., 2001. Recent advances on the nutritional effects associated with the use of garlic as a supplement. *J. Nutr*, **131**(3), pp.955S-962S.
4. Amagase, H., 2006. Significance of garlic and its constituents in cancer and cardiovascular disease. *Journal of nutrition*, **136**(3), pp.716-725.
5. Ansari, G., Morovati, S. P., & Asgary, S. (2018). Evaluation of four pulpotomy techniques in primary molars: A randomized controlled trial. *Iranian Endodontic Journal*, **13**(1), 7.
6. Bang, H. and Zhao, H., 2012. Average cost-effectiveness ratio with censored data. *Journal of biopharmaceutical statistics*, **22**(2), pp.401-415.
7. Bhatwalkar, S.B., Mondal, R., Krishna, S.B.N., Adam, J.K., Govender, P. and Anupam, R., 2021. Antibacterial properties of organosulfur compounds of garlic (*Allium sativum*). *Frontiers in Microbiology*, **12**, p.1869.
8. Caicedo, R., Abbott, P. V, Alongi, D. J., & Alarcon, M. Y. (2006). Clinical, radiographic and histological analysis of the effects of mineral trioxide aggregate used in direct pulp capping and pulpotomies of primary teeth. *Australian Dental Journal*, **51**(4), 297–305. doi:https://doi.org/10.1111/j.1834-7819.2006.tb00447.x
9. Carti, O., & Oznurhan, F. (2017). Evaluation and comparison of mineral trioxide aggregate and biodentine in primary tooth pulpotomy: Clinical and radiographic study. *Nigerian Journal of Clinical Practice*, **20**(12), 1604–1609.
10. Casella, S., Leonardi, M., Melai, B., Fratini, F., & Pistelli, L. (2013). The Role of Diallyl Sulfides and Dipropyl Sulfides in the In Vitro Antimicrobial Activity of the Essential Oil of Garlic, *Allium sativum* L., and Leek, *Allium porrum* L. *Phytotherapy Research*, **27**(3), 380–383. doi:https://doi.org/10.1002/ptr.4725
11. Dentistry, A. A. of P. (2008). *American Academy of Pediatric Dentistry*

- reference manual. American Academy of Pediatric Dentistry.
12. El-Saber Batiha, G., Magdy Beshbishy, A., G. Wasef, L., Elewa, Y.H., A. Al-Sagan, A., Abd El-Hack, M.E., Taha, A.E., M. Abd-Elhakim, Y. and Prasad Devkota, H., 2020. Chemical constituents and pharmacological activities of garlic (*Allium sativum* L.): A review. *Nutrients*, 12(3), p.872.
 13. Ezeorba, T.P.C., Chukwudozie, K.I., Ezema, C.A., Anaduaka, E.G., Nweze, E.J. and Okeke, E.S., 2022. Potentials for health and therapeutic benefits of garlic essential oils: Recent findings and future prospects. *Pharmacological Research-Modern Chinese Medicine*, 3, p.100075.
 14. Faghihi, T., Haghgoo, R., Taghizade, F., Zareiyani, M., Mehran, M., & Ansari, G. (2021). The clinical and radiographic evaluation of *Allium sativum* oil (garlic oil) in comparison with mineral trioxide aggregate in primary molar pulpotomy. *Dental Research Journal*, 18, 100. doi:10.4103/1735-3327.330881
 15. Fallahinejad Ghajari, M., Mirkarimi, M., Vatanpour, M., & Kharrazi Fard, M. J. (2008). Comparison of pulpotomy with formocresol and MTA in primary molars: a systematic review and meta- analysis. *Iranian Endodontic Journal*, 3(3), 45–49.
 16. Goyal, P., Pandit, I. K., Gugnani, N., Gupta, M., Singla, N., & Singla, V. (2016). Clinical efficacy of various medicaments used for pulpotomy in primary molars—A comparative study. *International Journal of Research and Development in Pharmacy & Life Sciences*, 5(3), 2107–2116.
 17. Gupta, K., Thakur, V. B. S., Gupta, N., Sharma, A., Mahajan, A., & Gupta, K. (2018). Comparative evaluation of formocresol and electrosurgical pulpotomy in human primary teeth—An in vivo study. *International Journal of Forensic Odontology*, 3(1), 21.
 18. Huth, K. C., Paschos, E., Hajek-Al-Khatat, N., Hollweck, R., Crispin, A., Hickel, R., & Folwaczny, M. (2005). Effectiveness of 4 Pulpotomy Techniques—Randomized Controlled Trial. *Journal of Dental Research*, 84(12), 1144–1148. doi:10.1177/154405910508401210
 19. Kahvand, M., Mehran, M., Haghgoo, R., & Faghihi, T. (2019). Clinical and Radiographic Evaluation of *Allium sativum* Oil (Garlic Oil) in Comparison with Formocresol in Primary Molar Pulpotomy. *Journal of International Society of Preventive & Community Dentistry*, 9(4), 390–395. doi:10.4103/jispcd.JISPCD_145_19
 20. Kalra, M., Garg, N., Rallan, M., Pathivada, L., & Yeluri, R. (2017). Comparative Evaluation of Fresh Aloe barbadensis Plant Extract and Mineral Trioxide Aggregate as Pulpotomy Agents in Primary Molars: A 12-month Follow-up Study. *Contemporary Clinical Dentistry*, 8(1), 106–111. doi:10.4103/ccd.ccd_874_16
 21. Madan, K., Baliga, S., Deulkar, P., Thosar, N., Rathi, N., Deshpande, M., & Bane, S. (2020). A comparative evaluation between propolis and mineral trioxide aggregate as pulpotomy medicaments in primary molars. *J Evol Med Dent Sci*, 9, 1256–1260.

22. MAGNUSSON, B. (1970). Attempts to predict prognosis of pulpotomy in primary molars Bacteriologic and histologic examination. *European Journal of Oral Sciences*, **78**(1–4), 232–240. doi:<https://doi.org/10.1111/j.1600-0722.1970.tb02069.x>
23. Mohammad, S. G., & Baroudi, K. (2015). Bacteriological evaluation of *Allium sativum* oil as a new medicament for pulpotomy of primary teeth. *Journal of International Society of Preventive & Community Dentistry*, **5**(2), 125–130. doi:10.4103/2231-0762.155738
24. Mohammad, S. G., Raheel, S. A., & Baroudi, K. (2014). Clinical and Radiographic Evaluation of *Allium sativum* Oil as a New Medicament for Vital Pulp Treatment of Primary Teeth. *Journal of International Oral Health: JIOH*, **6**(6), 32–36.
25. Neamatollahi, H., & Tajik, A. (2006). Comparison of clinical and radiographic success rates of pulpotomy in primary molars using formocresol, ferric sulfate and mineral trioxide aggregate (MTA).
26. Smaïl-Faugeron, V., Glenny, A. M., Courson, F., Durieux, P., Muller-Bolla, M., & Fron Chabouis, H. (2018). Pulp treatment for extensive decay in primary teeth. *Cochrane Database of Systematic Reviews*, (5). doi:10.1002/14651858.CD003220.pub 3
27. Subramanyam, D., & Somasundaram, S. (2017). Clinical and Radiographic Outcome of Herbal Medicine Versus Standard Pulpotomy Medicaments in Primary Molars: A Systematic Review. *Journal of Clinical & Diagnostic Research*, **11**(10).
28. Sunitha, B., Puppala, R., Kethineni, B., K Mallela, M., Peddi, R., & Tarasingh, P. (2017). Clinical and Radiographic Evaluation of Four Different Pulpotomy Agents in Primary Molars: A Longitudinal Study. *International Journal of Clinical Pediatric Dentistry*, **10**(3), 240–244. doi:10.5005/jp-journals-10005-1443
29. Tawil, P. Z., Duggan, D. J., & Galicia, J. C. (2015). Mineral trioxide aggregate (MTA): its history, composition, and clinical applications. *Compendium of Continuing Education in Dentistry (Jamesburg, N.J. : 1995)*, **36**(4), 247–52; quiz 254, 264.
30. Team, R. C. (2023). R: A language and environment for statistical computing. R Foundation for Statistical Computing, Vienna, Austria. [Http://Www. R-Project. Org/](http://www.R-project.org/).