

Original Article

Patient Perception and Radiographic Assessment of Sinus Lifting Procedure using Densah Bur versus Osteotome-mediated sinus lifting: A Randomized Clinical Trial

Doaa Rostom¹, Salma Belal Eiid²

¹Prosthodontics Department, Faculty of Dentistry, Cairo University, Cairo, Egypt

²Oral and Maxillofacial Radiology Department, Faculty of Dentistry, Cairo University, Cairo, Egypt

Email: Doaa.heshmat@dentistry.cu.edu.eg

Submitted: 30-5-2020

Accepted: 16-4-2021

Abstract:

Aim: This study aimed to evaluate the patient perception towards osteotome and densah burs in sinus lifting procedures and to assess the new bone generated using CBCT at 6 months post-operatively. The study hypothesis was that densah bur would show comparable results to osteotome-mediated sinus lifting.

Subjects and methods: Ten patients were enrolled in the study with atrophied maxillary posterior edentulous area that required rehabilitation with implants and sinus membrane elevation. Sinus membrane was elevated with two techniques, Osteotome and Densah bur sinus lifting procedures. Clinical (sinus perforation, post-operative swelling, and headache/vertigo) and radiographic parameters (residual bone height (RBH) and endo-sinus bone gain (ESBG)) were assessed.

Result: In both groups, new bone levels were higher in comparison to initial levels with statistical significant difference. Densah bur showed higher mean ESBG than osteotome group with values 1.8 ± 0.4 and 1.4 ± 0.5 respectively ($p = 0.21$). Post-operative complications comparison showed non-significant differences between both groups except for headache and vertigo.

Conclusion: The protruded implants can act as tents and allow formation of blood clot with concomitant bone regeneration. Although the two techniques applied for drilling showed comparable radiographic results, however, they displayed differences in patient perception. According to this study, it can be concluded that osseodensification may surpass osteotome- lifting procedure when it comes to patient comfort and satisfaction.

Key words: Sinus lifting, CBCT, Densah bur

Introduction

Maxillary posterior edentulous area rehabilitation with implants is usually not an easy procedure and is considered a challenge to many prosthodontists. This is due to pneumatization of the maxillary

sinus, poor bone density and volume, and difficult accessibility of this area.¹ Since rehabilitation in the maxillary posterior area depends on the quantity and quality of bone available, the placement of dental implant in the best prosthetic

position requires regenerative surgical techniques to correct the initial anatomical situation.²

Summer in 1994 introduced a less invasive technique than the conventional lateral approach sinus floor elevation called the closed sinus lifting. **Summer** classified it in to osteotome sinus floor elevation and bone-added osteotome sinus floor elevation. Osteotome depends on condensing the bone in implant bed site and pushing it laterally and upward raising the sinus floor. Although being successful and non-invasive, Summer's technique showed several surgical problems as heat generation-induced necrosis if not well irrigated, delayed implant secondary stability, and some patient-related drawbacks as headache and vertigo.³

In 2014, **Salah Huwais** introduced new burs called densah burs that help preservation of bone health by condensing rather than removing bone and it was labeled osseodensification. In the past few years since the introduction of densah burs, limited number of studies evaluated its efficiency as well as patient perception to the procedure.³

It is well established that cone beam computed tomography (CBCT) gives more profound and accurate assessment for pre- and post-operative implant sites in comparison to conventional techniques. Nevertheless, a meta-analysis was published in 2018 showed that most previous studies on lifting procedures used conventional 2D techniques, and very few applied CBCT as the diagnostic modality. This heterogeneity highly affected the quality of evidence retrieved.⁴

Therefore, this study aimed to evaluate patient perception to osteotome and densah burs, as well as to assess the new bone generated at 6 months post-operatively using CBCT. The study hypothesis was that densah bur would show comparable results to osteotome-mediated sinus lifting.

Subjects and Methods:

This was a hospital-based randomized (1:1) parallel-group study conducted in Egypt. Sample size calculation was based on the radiographic outcome of endo-sinus bone gain. According to

Suk-Arj et al,¹¹ the endo-sinus bone gain in the osteotome group was 1.96 ± 0.67 mm and the estimated minimum clinical important difference was 1.3 based on expert's opinion. By adopting a two-sided 5% significance level and a power of 80%, a predicted sample size of 5 patients per group was necessary. Sample size calculation was performed using PS version 3.1.2. This present study was conformed and reported according to the CONSORT guidelines and registered in ClinicalTrials.gov.

Patient Enrollment:

This study took place in Faculty of Dentistry, Cairo University. Ten patients were enrolled in this prospective randomized clinical trial (2 males and 8 females with an age range from 25 to 55). All patients were partially edentulous with atrophied posterior maxilla. Patients were selected from the Outpatient Clinic. They were recruited according to the following criteria, where, the residual bone height at the site of implant placement was 8 mm. All patients were in a good health, non-smokers with no systemic, immunologic or debilitating diseases that could affect normal bone healing. Their edentulous ridges were covered with optimal thickness of mucoperiosteum with no signs of inflammation, ulceration or scar tissue and sufficient inter arch space adequate for future prosthesis.

After patient selection according to the eligibility criteria, patients were assigned to one of two groups either osteotome (control group) or densah bur group (intervention group). Randomization was done using online software (Random.org) and allocation concealment was generated through the use of sealed opaque envelopes. Patients, radiologist and statistician were completely blinded to all data.

Patient Preparation and Surgical Procedures:

For both groups, pre-operative extra-oral photograph with panoramic radiograph for initial screening were taken. Impressions for upper and lower arches were recorded and then face bow transfer was accomplished. Prosthetic wax-up

fabrication and pre-surgical stent were performed for evaluation of implant placement. Moreover, for each patient, CBCT was performed before sinus lifting procedure (T0) and 6 months postoperatively (T1). Data were acquired by standardizing CBCT parameters (10 mA, 12 kVp, 0.4 voxel size). For analysis, *Planmeca Romexis software version 4.6.2.R.* was used.

For both groups, local anesthesia was injected at the implant site and a midcrestal incision with buccal and palatal mucoperiosteal flaps reflected in a full-thickness exposing the crestal part of the alveolar ridge. First we started with 2 mm pilot drill, the drill was inserted to depth 1mm away from the sinus floor to prevent the tip of the drill from rupturing the schneiderian membrane.

For osteotomy group (control group), a set of concave osteotomes with different dimensions was sequentially used to widen the osteotomy site using a surgical mallet. First of all, osteotome size 2.5 mm was inserted into the osteotomy to a depth 1 mm away into the sinus with light malleting by the nylon cap mallet. Then, 3 mm osteotome was used to fracture up the sinus floor and finally 3.5 mm osteotome was tapped gently to elevate the sinus floor to the desired depth of the implant in the maxillary sinus.

Regarding densah group (intervention group) as shown in **Figure (1)** and according to the densah protocol. After making initial perforation close to the sinus floor, the direction was reversed and the cutting speed was raised to 1200 rpm. Thereafter, 2 successive densah burs were used to elevate sinus membrane 2 mm and to prepare implant hole to the selected implant size. For both groups, the selected implant size was 4.2 mm in width and 10 mm in length.

Post-operative Complications Recording:

After drilling both groups, the integrity of the membrane was assessed with valsalva maneuver. Clinical evaluation and patient perceptions for headache or vertigo and post-operative swelling were assessed 7 days post-operatively. Two HRQOL questionnaires were merged and adjusted to be used in this study.^{14, 15}

The questionnaire was presented by an examiner not involved in the surgery and the number of events were recorded and statistically analyzed.

CBCT Image Analysis:

Scans Standardization:

Since no radiopaque markers were used to correlate pre and post scans, standardization was a mandatory step in optimizing the measurement phase. First of all, the volume was oriented that the hard palate and the axial reference line were parallel to each other. Second, standardization was conducted by choosing a specific axial cut in the post-operative scan with a clear anatomic reference point (e.g. lateral pterygoid plate, certain notch in the maxilla, or a scan with the largest diameter of the incisive foramen). This step differed from patient to patient, however, the protocol remained the same in choosing a certain clear image reference structure. Then, the sagittal reference line was adjusted parallel and midway to cortices and the coronal hairline touched a specific surface that is common in pre-and post-scans (e.g. the distal surface of first premolars) (**Fig. 2**). Thereafter, the number of slices was counted to reach the mid implant cut on the post-operative scans. This was replicated in the pre-operative scan after optimizing the cut thickness and image gap.

Radiographic Outcomes:

A trained radiologist with 10 years experience evaluated the following radiographic outcomes:

- a. *The residual alveolar bone (RBH)*, which was defined as the distance from the alveolar crest to the sinus floor at the intended implant site.
- b. *The new bone ridge length*, which was measured as the distance between the alveolar crest to the first visualized bone contacting the implant body.
- c. *Endo sinus bone gain (ESBG)* was extracted by subtracting both values to determine the amount of bone formed in such period

“RBH – New bone level = ESBG”.

Measurements were taken at three consecutive sections in the pre and post-operative scans. In

both coronal and sagittal images, new bone was measured on mesial or distal and buccal or lingual surfaces according to which surface bone is mostly visualized in (Fig. 3). Next, the mean from the

occasions one week apart. The radiologist was blinded to the details of the patients' surgery and other pre-specified outcomes.

Statistical analysis:

Regarding post-operative complications, comparison of proportions was performed using the Z test. Comparison between residual bone height and new bone level as well as ESBG versus RBH was achieved using independent t-test. In

three sections was calculated and the total of both sagittal and coronal means was used as the final value. To assess the intra-examiner agreement, the radiographic parameters were evaluated on two addition to that, the correlation between the RBH and ESBG was evaluated using Pearson's correlation coefficient. Lastly, intra-observer reliability was performed using Cronbach's alpha reliability coefficient. Continuous data were presented as mean and standard deviation, whereas number of events was presented as proportions. Statistical analysis was performed with SPSS 16® (Statistical Package for Scientific Studies), Graph pad prism & windows excel.

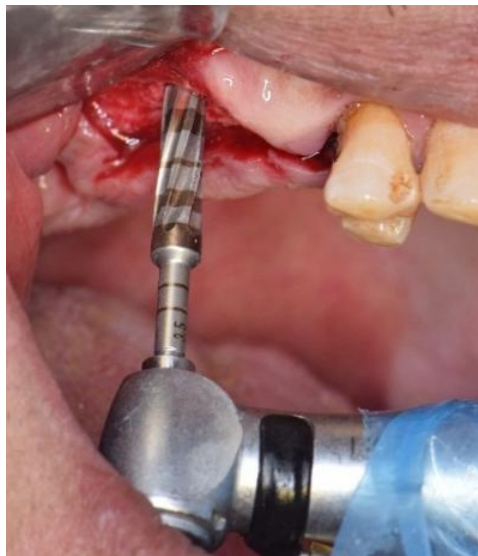

Figure (1): Clinical picture of Densah bur during drilling

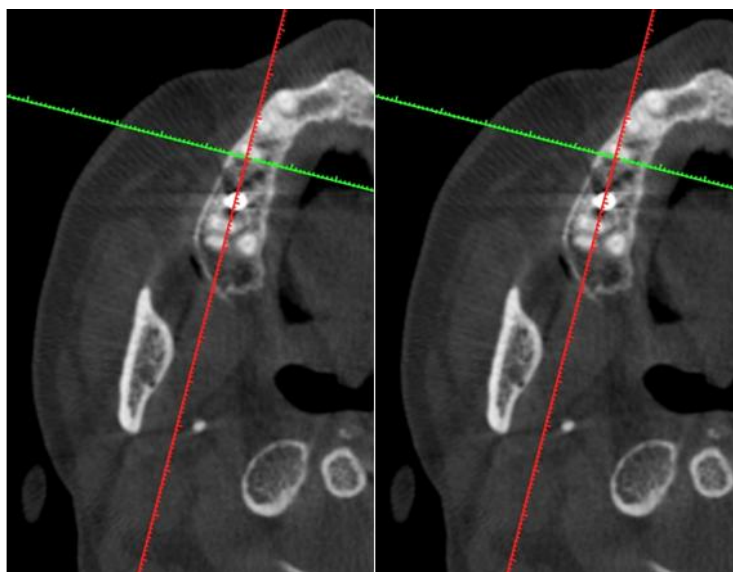


Figure (2). After selection of an axial cut in T0 and T1, the sagittal (red line) and coronal (green line) reference lines were adjusted simultaneously in both scans passing through the chosen common anatomical landmarks in both views.

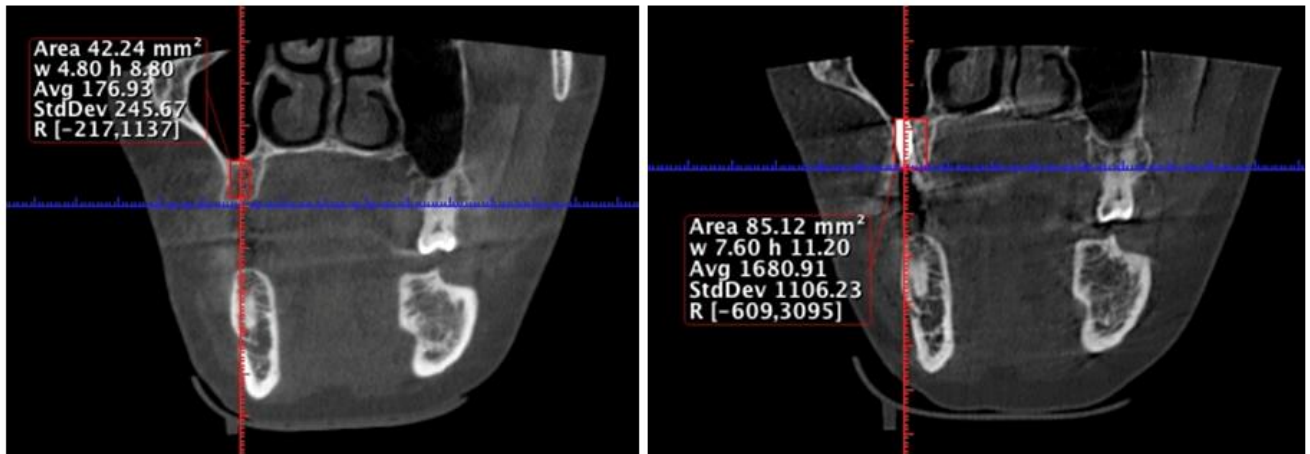


Figure (3). Pre (left) and post-operative (right) CBCT scans for the same patient showing the increase in alveolar bone height after 6 months.

Results:

In both groups, new bone levels were higher in comparison to initial ones with statistical significance as presented in **Table (1)**. Intervention group (densah bur = 1.8 ± 0.4) showed higher mean ESBG than the control group (osteotome = 1.4 ± 0.5) but with no statistical significant difference ($p = 0.21$) as presented in **Table (2)** and **Figure (4)**.

The mean RBH in Densah bur group (8.1 ± 1.5) was higher than osteotome sinus lifting (6.9 ± 0.6) but with no statistical significant difference reported ($p = 0.13$). Correlation between ESBG and RBH revealed medium negative correlation in osteotome group ($r = -0.66$), whereas, strong positive correlation was exhibited ($r = 0.9$) in densah bur group as presented in **Table (2)**. Intra-observer reliability assessment showed values above 0.8 (very good to excellent agreement) (**Table 3**).

Chi square test was used for post-operative complications comparison and it showed non-significant differences between both groups except for headache and vertigo with a $P < 0.05$ as presented in **Table (4)**.

Discussion :

Along the years, many clinicians searched for the practicality of graft-free osteotomy procedures, which proved successful but with

reported patient discomfort.^{5, 6} A meta-analysis in **2019** stated that the intra and postoperative complications that might occur with osteotome-mediated lifting procedure are infection, exposure of the covering membrane, swelling, mild postoperative edema, pain, nose bleeding, headache and vertigo. The psychosocial patient status after sinus lifting using different techniques is very important in the clinical practice to determine which technique is associated with the least drawbacks.⁷ Recently, transcresal sinus elevation with osseodensification showed lower clinical complaints than osteotome technique but paucity of in-vivo studies in literature is still of concern.⁵

In transcresal sinus elevation, the recommended technique for osseodensification is to use the burs in the osseodensifying mode with a pumping motion with copious irrigation. In the present study, copious irrigation was used to provide lubrication between the bur and bone surfaces and eliminate overheating. Densah burs herein were used with a standard surgical motor and irrigation but rotated counterclockwise at 800 to 1,200 rpm for densification. It has a large negative rake angle with a chisel edge and a tapered shank that progressively increases diameter, but with controlled expansion process. The fluid pumping method coupled with high-speed counterclockwise rotation induces a hydrodynamic wave termed the compression wave ahead of the point of contact.

Table (1): Comparison between RBH and new bone level in both groups

Group	N	Osteotome			Densah bur		
		M.	SD.	P	M.	SD.	P
RBH	5	6.9	0.51	0.001*	8.3	1.58	0.016*
New bone level	5	8.27	0.48		10.8	1.1	

Table (2): Comparison between osteotome and densah bur regarding ESBG and RBH and correlation between ESBG and RBH in both groups

Group	N	ESBG			RBH			r
		M.	SD.	P	M.	SD.	p	
Group I (Osteotome)	5	1.4	0.5	0.21	6.9	0.6	0.13	- 0.66
Group II (Densah bur)	5	1.8	0.4		8.1	1.5		0.93

*r: correlation

Table (3): Reliability between 1st and 2nd readings regarding RBH, new bone level and ESBG in both Groups

	Osteotome	Densah bur
RBH	0.97	0.96
New bone level	0.89	0.88
ESBG	0.87	0.86

Table (4): Comparison of post-operative complications between both groups:

Complication	N	Group I Osteotome		Group II Densah bur		P value
		N	%	N	%	
Headache & vertigo	5	5	100	0	0	0.002*
Swelling	5	4	80	2	40	0.22
Sinus membrane perforation	5	0	0	0	0	1.00

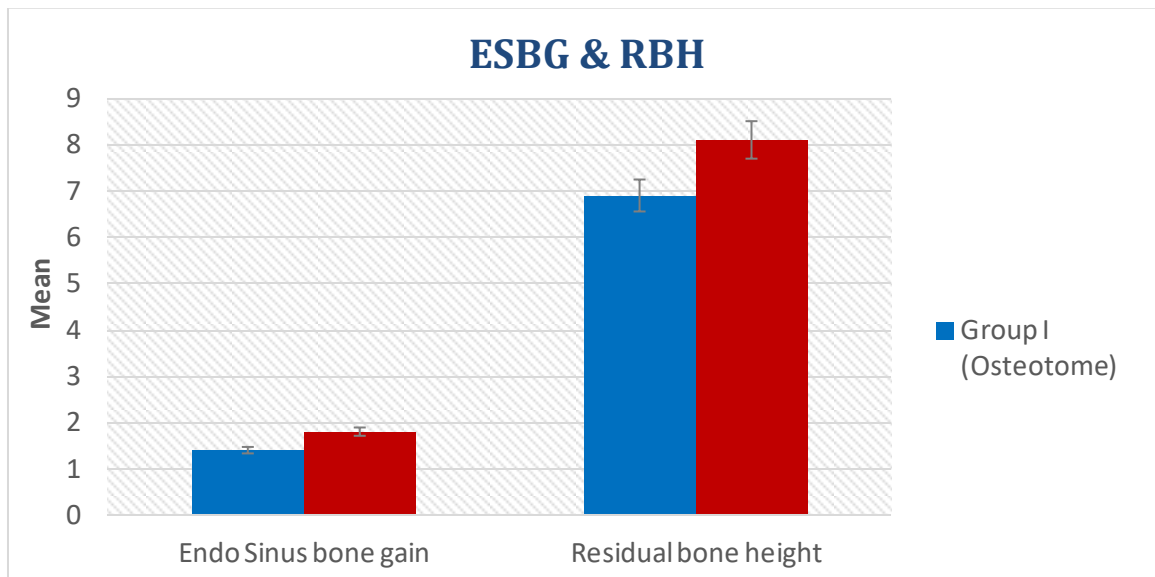


Figure (4). Comparison between osteotome and densah bur regarding ESGP and RBH

Osseodensification has the capacity to prepare the implant site while elevating the sinus membrane with low risk of perforation, minimal postoperative complications, as well as facilitating autogenous bone grafting to enhance implant stability. These capabilities are based on a combination of hydrodynamic wave action and hydraulic compression.^{5,6}

Generally, the most commonly reported intraoperative complication of sinus lifting is membrane perforation. It has been reported to occur in 7-35% of sinus floor elevation procedures. Fortunately, in our study the rate of membrane perforation was null for both groups. Regarding postoperative complications⁸, a clinical study reported that peri-implant infections and swelling of all types of implant therapy are very common problems where swelling occurred in 80% of the subjects and in 50% of the implant sites and peri-implantitis has been identified in 28-56% of the subjects and in 12-43% of the implant sites⁹. In this study in hand, both groups showed postoperative swelling but wasn't statistically significant, where osteotome group showed 80% (4 out of 5 cases) while densah bur treatment presented with 40% swelling (2 out of 5 cases).

Moreover, vertigo and a sensation of whirling and loss of balance is one of the main

complications associated with the sinus membrane elevation using osteotomes, which mainly decreases within several days to weeks. In the present study, the vertigo rate with osteotome treatment was 100% whereas in densah bur group, none of the cases reported any of the manifested vertigo symptoms. This was explained in a randomized controlled trial that osteotome may causes detachment of the otolith. The detached otolith may move into the posterior semicircular canal because of patient hyperextended and tilted head position during surgery. That is why the use of osteotome and malleting for closed sinus floor elevation is associated with a higher risk of pain and vertigo.⁹

When it comes to assessment of radiographic outcomes as indirect markers of successful lifting procedure, Yan and his group carried out a meta-analysis in **2018** assessing marginal bone height and endo-sinus bone gain. One of the main limitations in this meta-analysis was the heterogeneity of using conventional and cross-sectional techniques in included RCTs, which negatively affected the quality of evidence. In this study, cone beam computed tomography was chosen to standardize assessment of changes in the 6 months follow-up.⁴

High success rate in osteotome lifting procedures has been reported in literature and this was ascribed to the osteogenic activity and potential of the sinus membrane in producing de novo bone. In 2016, a study by **Nedir et al**¹⁰ assessed long term outcomes in osteotome lifted cases and showed that the mean increase in bone height around the implants was 3.0 ± 1.4 mm at 10 years follow-up period. The bone tended to increase in the first three years and then became stable afterwards. In 2019, **Suk-Arj et al**¹¹ conducted a study on osteotome sinus floor elevation without grafting material with short term 6 months follow-up period. They revealed that the average of ESBG was 1.80 ± 0.79 mm and 1.96 ± 0.67 mm in the coronal and sagittal view respectively.¹⁰ This reporting is in line with ours, where the bone gain was apparent in all osteotome cases with an average value of 1.4 ± 0.5 mm.

In 2019, a study carried by **Arafat & Elbaz**¹² to evaluate the differences between osteotome versus osseodensification. They stated that both groups showed statistically significant increase in bone height, which coincided with our work findings. Their results showed that osseodensification group showed higher ESBG values (3.33 ± 0.25) than that of the osteotome group (2.79 ± 0.30) with significant difference. This finding was somehow in concordance with ours, where osseodensification group (1.8 ± 0.4) exhibited a slightly higher value than that of the osteotome group (1.4 ± 0.5) but with no significant difference (p value = 0.21).

It was suggested that this may be due to that osseodensification induces compactness of bone chips on the osteotomy site walls and therefore, faster secondary stability achievement.¹² Likewise, a recent systematic review highlighted the efficiency of densah burs in such field and osseodensification showed higher percentage of bone volume, increased bone to implant contact, as well as improved bone density¹³

There is a conflict in literature that newly formed bone depends on the residual bone height, where it was claimed by **Nedir et al in 2016**¹⁰ that higher ESBG is usually associated with lower residual

bone ridge. Nonetheless, **Yang, et al 2019**⁷ suggested that no correlation could be extrapolated from both factors. Our findings were equivocal, where osteotome group showed moderate inverse correlation between the residual bone height and ESBG, where as densah bur osteotomy exhibited a positive strong correlation. The notion that both techniques behaved differently with the amount of residual bone present can't be inferred from such small sample.

In this study in hand, the evaluation of the reliability and reproducibility of the CBCT measurements was a mandatory step. Results demonstrated a very good to excellent intra-observer agreements denoting that measurements used for the ESBG and RBH were reliable and reproducible.

Conclusion

According to this study, it can be supposed that implants can retain an empty space perfectly and act as a tent for a following bone generation process. Moreover, the two ways of drilling showed comparable radiographic results, however, displayed differences in patient perception. Therefore, it can be inferred that osseodensification may surpass osteotome-lifting procedure when it comes to patient comfort and satisfaction. Nowadays, since patient contentment is one of the main prerequisites in the dental field, this notion may become very empowering in the very near future. Nevertheless, as a limitation, this study just focused on a small sample group with a short duration follow-up period. Underpowered trials may pave a good path in gaps of knowledge and can be used in systematic reviews and meta-analyses, nevertheless, conduction of randomized trials with larger scale and longer duration is highly advocated to get a more profound picture about differences in both techniques.

Reference :

1. Bartee BK. "Extraction site reconstruction for alveolar ridge preservation. Part 1: rationale and materials selection." J Oral Implantol 2001; 4:187-193.

2. Rosen M., and Sarnat B. "Change of volume of the maxillary sinus of the dog after extraction of adjacent teeth." *Oral Surg, Oral Med, Oral Pathol and Oral Radiol.* 1955; 8(4):420-429.
- 3 .Huweis, S, and Meyer EG. "A Novel Osseous Densification Approach in Implant Osteotomy Preparation to Increase Biomechanical Primary Stability, Bone Mineral Density, and Bone-to-Implant Contact." *Int J Oral Maxillofac Implants* 2017; 32(1): 27-36
4. Yan M, Liu R, Bai S, Wang M, Xia H, Chen J. Transalveolar sinus floor lift without bone grafting in atrophic maxilla : A meta-analysis. *Sci Rep.* 2018;8(1045):1–9.
5. Coelho PG, and Jimbo R. "Osseointegration of metallic devices: current trends based on implant hardware design." *Arch Biochem Biophys* 2014;561: 99-108.
6. Seong, WJ, Kim UK, Swift JQ, Heo YC, Hodges JS, Ko CC. "Elastic properties and apparent density of human edentulous maxilla and mandible." *Int J Oral Maxillofac Surg.* 2009;38(10): 1088-1093
7. Yang J, Xia T, Wang H, Cheng Z, Shi B. Outcomes of maxillary sinus floor augmentation without grafts in atrophic maxilla : A systematic review and meta - analysis based on randomised controlled trials. *J Oral Rehabil.* 2019;46(3):282–290.
- 8 .Shlomi B, Horowitz I, Kahn A, et al. The effect of sinus membrane perforation and repair with Lambone on the outcome of maxillary sinus floor augmentation: a radiographic assessment. *Int J Oral Maxillofac Implants.* 2004; 19(4):559-562.
9. Vernamonte S, Mauro V, Vernamonte S, Messina AM. An unusual complication of osteotome sinus floor elevation: benign paroxysmal positional vertigo. *Int J Oral Maxillofac Surg* 2011; 40(2):216–218.
10. Nedir R, Nurdin N, Vazquez L, Abi Najm S, Bischof M. Osteotome Sinus Floor Elevation without Grafting: A 10-Year Prospective Study. *Clin Implant Dent Relat Res.* 2016;18(3):609–17.
11. Suk-Arj P, Wongchuensoontorn C, Taebunpakul P. Evaluation of bone formation following the osteotome sinus floor elevation technique without grafting using cone beam computed tomography : a preliminary study. *Int J Implant Dent.* 2019;5(1):27.
- 12.Arafat SW, Elbaz MA. Clinical And Radiographic Evaluation Of Floor Elevation In Partially Atrophic Maxilla : A Prospective Long Term Study. *Egypt Dent J.* 2019;65(1):189–195.
13. Pai UY, Rodrigues SJ, Talreja KS, Mundathaje M. Osseodensification – A novel approach in implant dentistry. *J Indian Prosthodont Soc.* 2018;18(3):196–200.
14. Mardinger, O., Poliakov, H., Beitlitum, I., Nissan, J., & Chaushu, G. (2009). The Patient's Perception of Recovery after Maxillary Sinus Augmentation: A Prospective Study. *Journal of Periodontology*, 80(4), 572–576. doi:10.1902/jop.2009.080536
15. Savin J, Ogden GR. Third molar surgery: A preliminary report on aspects affecting quality of life in the early postoperative period. *Br J Oral Maxillofac Surg* 1997;35:246-253.